



---

# Clinical and Medico-legal Aspects of Maxillofacial and Neck Injuries Complicated by Infection

Vyacheslav Popov<sup>1,2</sup>, Olga Egorova<sup>1,3</sup>

<sup>1</sup>Department of Forensic Medicine and Law, Pavlov State Medical University, Saint Petersburg, Russia

<sup>2</sup>Department of Public Law, Admiral Makarov State University of Maritime and Inland Shipping, Saint Petersburg, Russia

<sup>3</sup>Department of Stomatology, Mechnikov North-Western State Medical University, Saint Petersburg, Russia

## Email address:

egorova\_ohta@mail.ru (O. Egorova)

## To cite this article:

Vyacheslav Popov, Olga Egorova. Clinical and Medico-legal Aspects of Maxillofacial and Neck Injuries Complicated by Infection.

*International Journal of Clinical Oral and Maxillofacial Surgery*. Vol. 5, No. 2, 2019, pp. 42-46. doi: 10.11648/j.ijcoms.20190502.12

**Received:** March 31, 2019; **Accepted:** October 5, 2019; **Published:** October 24, 2019

---

**Abstract:** One of the most frequent and predictable types of complications in traumas of the maxillofacial area and neck is that of infection, which renders the progression of the trauma more acute. It is infection, when it occurs, that affects the clinical picture and determines the final outcome of the trauma. Inadequate medical methods exacerbate the severity of the progression of the trauma and, consequently, complicate forensic medical assessment of the injury. Nowadays there is no clear definition of acute inflammatory process severity in terms of prevalence and characteristics of its clinical course in maxillofacial area and neck injuries. The aim of our study is to improve criteria for assessing the severity of harm to human health in patients with injuries of the maxillofacial area and neck. We carried out a retrospective analysis of medical records of the inpatients treated from 2008 to 2019 in the department of Oral and Maxillofacial Surgery of St. Petersburg City Hospital No. 15, Russia. All patients had the injuries in the maxillofacial area and neck varying in severity and complicated by infectious processes, differing in their prevalence in the cellular spaces of the maxillofacial area and neck. In all these cases surgery was attempted, but it was not always adequate and timely, which made it more difficult for medical forensics experts to assess the severity of harm to human health resulting from the injury. The results of the study confirm the need to implement the modernized criteria for assessing the severity of harm caused to human health in case of injuries in the maxillofacial area and neck complicated by infectious processes. Their implementation will help bridge the gap between practical needs and the capabilities of forensic medical examination

**Keywords:** Maxillofacial and Neck Injuries, Infectious Complications, Harm to Human Health

---

## 1. Introduction

According to the current legislation of the Russian Federation, any medical doctor can be summoned as an expert medical witness in order to take part in a forensic examination aiming to determine the severity of harm caused to human health. In this context, involvement of a maxillofacial surgeon in the work of respective evaluation teams is a requirement. However, professional experience shows that, in some cases, forensic medical experts face issues that require expertise in the field of related clinical disciplines. This especially concerns injuries to the maxillofacial area and neck that are accompanied by infectious processes, due to the anatomical diversity and

frequent spreading of the inflammatory processes with the development of septic forms of inflammation in this category of patients. Infection is one of the most frequent and predictable complications of injuries to the maxillofacial area and neck. It is infection, when it occurs, that affects the clinical picture and determines the final outcome of the trauma [1-3, 4-7, 10]. Inadequate medical, diagnostic, and organizational methods exacerbate the severity of the progression of the trauma and, consequently, complicate forensic medical assessment of the injury. In our expert practice, we have repeatedly encountered cases where the opinions of clinicians regarding the severity of the injury and its consequences were in conflict with the forensic medical assessment of damage to health. The fact that when qualifying the degree of severity of harm caused to human

health as a result of an injury accompanied by infectious processes, forensic experts do not take into account inflammatory complications that aggravate the injury, negatively affect the forensic medical characteristics of such injuries, and therefore, the legal assessment of a tort. This research aims to improve criteria for assessing the severity of harm to human health in patients with injuries of the maxillofacial area and neck complicated by infectious processes [1, 11-14].

## 2. Methods

We carried out a retrospective analysis of medical records of the inpatients treated from 2008 to 2019 in the department

of Oral and Maxillofacial Surgery of St. Petersburg City Hospital No. 15, Russia. The data were collected from medical records of 801 patients. All patients had the injuries in the maxillofacial area and neck varying in severity and complicated by infectious processes, differing in their prevalence in the cellular spaces of the maxillofacial area and neck. Among them were 618 men and 183 women. Twelve of these patients died from the purulent complications of the maxillofacial trauma. Infectious complications of trauma were more common in the age group of 30–39 years, which was 30.8% of the total number of observations. The distribution of patients by gender and age is shown in the Figure 1.

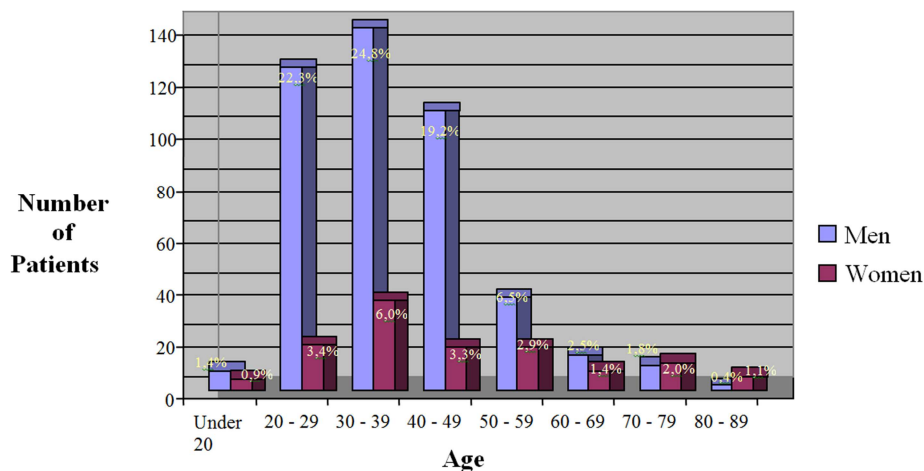


Figure 1. Distribution of patients by gender and age.

As can be seen from the figure, men of working age 30–39 years prevailed among the patients. By the nature of the injury the blunt force trauma mainly prevailed - 540 cases (67.4%). The injuries with sharp objects were observed in fifteen cases (1.9%). In four cases (0.5%) gunshot injuries were noted and in one case (0.1%) - a wound from an air gun was noted.

## 3. Results

Having analyzed the clinical material we found that the infectious complications varied widely: from local suppurative processes developing directly in the area of injury to ones which spread through cellular spaces beyond the maxillofacial area and neck - in particular, to the mediastinum, with subsequent spreading of the infection

leading to death from sepsis. Therefore, we identified three main groups of patients depending on the degree and depth of the lesion of the mandibular cellular spaces and neck. They are: the local inflammatory processes characterized by the presence of a limited focus of inflammation in the area of an injury – the first degree of prevalence; the inflammatory processes extending to 1-3 adjacent cellular spaces without involvement of deep cellular spaces of the neck in the process - the second degree of prevalence and common inflammatory processes with injury to more than four cellular spaces with involvement of deep cellular spaces of the neck in the process – the third degree of prevalence. The characteristic of injuries of the maxillofacial area complicated by an inflammatory process depending on the prevalence of an acute inflammatory process is presented in Table 1.

Table 1. Distribution of the patients with injuries of the maxillofacial area and neck depending on the age and extent of an acute inflammatory process.

Age (years)	Local process (the first degree of prevalence)	1-3 adjacent cellular spaces (the second degree of prevalence)	More than 4 cellular spaces (the third degree of prevalence)	Total
Up to 20	14	0	3	17
20 – 29	135	51	8	194
30 – 39	184	64	13	261
40 – 49	128	33	9	170
50 – 59	66	11	3	80
Over 60	72	6	1	79
Total	599	165	37	801

We analyzed the treatment results and concluded that in the most cases (599 patients) there were local inflammatory processes localized in the lesion zone and characterized by the soft tissues abscess. We distinguished three groups of the patients depending on the localization of injuries: the patients

with injuries of soft tissues; the patients with fractures of the lower jaw and the patients with trauma to the middle zone of the face. The distribution of the patients according to the location of an injury is presented in the Table 2.

*Table 2. The distribution of the patients according to the location of an injury.*

Age (years)	Injuries of soft tissues	Fractures of the lower jaw	Trauma to the middle zone of the face	Total
Up to 20	12	5	0	17
20 – 29	77	106	11	194
30 – 39	109	144	8	261
40 – 49	76	90	4	170
50 – 59	43	36	1	80
Over 60	73	5	1	79
Total	390	386	25	801

It follows from the table that soft tissue injuries were the most common. Infectious complications varied widely: from local suppurative processes developing directly in the area of injury to ones which spread through cellular spaces beyond the maxillofacial area and neck - in particular, to the mediastinum, with subsequent spreading of the infection leading to death from sepsis. In all these cases surgery was attempted, but it was not always adequate and timely, which made it more difficult for medical forensics experts to assess the severity of harm to human health resulting from the injury.

#### 4. Discussion

Introduction of “Medical Criteria for determining the severity of harm to human health” in Russian legislation (approved by the Order No. 194n of the Ministry of health and social development of the Russian Federation on April 24, 2008) the inflammatory complications of injury, including the maxillofacial area and neck, began to be taken into account when qualifying the severity of harm caused to human health.

The clauses 6.2.7 (on life-threatening purulent-septic condition) and 25 (on the assessment of failures in the provision of medical care as causing harm to health) in the existing “Medical Criteria” allow us to give clear assessments of the severity of harm caused to human health in cases where injuries to the maxillofacial area and neck are complicated by purulent inflammatory processes. Nevertheless, the clause 6.2.7 does not disclose the severity of the acute inflammatory process in terms of prevalence and also does not concern the clinical features of the acute inflammatory process in the maxillofacial area and neck. In connection with the above, two cases from clinical and professional practice illustrate the collision.

Case 1. K., 37 years old, male, was brought to hospital some hours after being stabbed in the neck. On admission, the patient had a horizontal linear wound of 2-2.5 cm in anterior area of the neck in the cricoid cartilage, and a subcutaneous emphysema. A review of the wound revealed tracheal damage. The surgeon parted the edges of the tracheal wound and installed a tracheostomy cannula in its lumen.

Case follow-up by an intensive-care physician was prescribed. Within four days, the patient's condition was stable; however, psychomotor agitation and aggressiveness were noted in the patient. The following treatment was prescribed: antibacterial therapy, re-dressing of the neck wound, and disinfection of the tracheostomy tube. On the fifth day after the injury, the patient's condition deteriorated sharply. Respiratory and cardiac arrest occurred. Resuscitation was ineffective. The patient was declared biologically dead. The forensic medical examination of the corpse revealed the presence of an anterior neck area stab and slash wound with the injuries to the trachea, the esophagus and the spine, penetrating the lumen of the trachea, the esophagus and the vertebral canal. The following complications were noted: mediastinitis, tracheitis, esophagitis, and leptomeningitis. Thus, K., aged 37, died as a result of the anterior neck area stab and slash wound with damage to the trachea, the esophagus, and the spinal column, complicated by purulent tracheitis, esophagitis, mediastinitis, leptomeningitis, intoxication, and multiple organ failure. On the criteria of danger to life, this injury is considered grievous harm to human health. In K.'s medical care, failures took place at every stage. Specifically, the standard set of diagnostic measures during the initial surgical treatment of the wound, including an x-ray examination of the neck and endoscopic examinations (bronchoscopy, esophagoscopy), was not fully implemented. A review of the posterior wall of the trachea and esophagus was not performed, as was revealed later by the autopsy. The severity of the overall condition of such a patient with a trachea wound was underestimated, and this led to an incorrect approach to treatment being adopted in the post-operative period. Undoubtedly, these shortcomings in the patient's medical care led to the development of the infectious complications and to the patient's death. The average mortality rate for injuries and complications similar to those noted in K., according to the data in the medical literature, is 30-40% [8, 9]. Therefore, providing timely and adequate medical care to such a patient could increase the chances of a favourable outcome [15]. There is a direct causal relationship between the stab and slash wound to K.'s neck and his death. In this case, the shortcomings of the medical care he received resulted in the

development of the complications, and are thus related to the lethal outcome indirectly, via a mediated causal relationship. According to the medical literature, neck injuries accompanied by damage to the trachea and esophagus are complicated by shock, impairment of consciousness, and subsequent purulent complications [5]. Patients with such injuries should be under the constant supervision of an on-call intensive care physician. When conducting the initial surgical debridement, the entire length of the wound tract should be examined. Non-viable, crushed parts of the edges of the tracheal wound are to be excised, in order to allow the tracheal damage to heal fully, and the postoperative wound is to be drained [10]. If the esophagus is damaged, tube feeding should be provided. This is necessary, since otherwise infection of the paravertebral (paraspinal) fat and the posterior mediastinum occurs, with subsequent development of mediastinitis. Thus, the numerous failures in the provision of K.'s medical care caused the development of the complications and contributed to the lethal outcome. A stab and slash wound to the front of the neck, with damage to the trachea, esophagus and spine, is life-threatening at the time of its occurrence. When interpreting the cause of death, there is reason to believe that there was a direct causal link between the injury and death. At the same time, in the case at hand, the following diagnostic pitfalls are observed: the esophagus and spinal injuries were not diagnosed, and the wound tract was not examined. Undoubtedly, these pitfalls had a negative impact on the patient's health and accelerated the onset of his death, but there is no sufficient reason to believe that they could cause his death independently, since the severity of the patient's condition was determined by the danger to his life resulting from the initial injury and the infectious complications that followed naturally.

Case 2. Patient G., 35 years old, male, was admitted to the Department of Maxillofacial Surgery in critical condition on the seventh day after being injured by a punch to the left buccal area. On admission, the temperature of his body was 38-39°C, with a weak pulse of 90 beats per minute. His skin was pale and covered with cold, sticky sweat. The patient complained of general weakness, sharp pains in the body and left corner of his lower jaw, restriction in opening his mouth, pain in swallowing, choking. Clinical hemanalysis established pronounced leucocytosis, a left-shift in the leucocytic formula, the appearance of immature forms of leucocytes, and an accelerated sed rate (ESR). It was ascertained from the patient's medical history that on the fifth day after the injury, he went to see the dental surgeon with a complaint about pain in the area of teeth number 37 and number 38. Teeth 37 and 38 were extracted, but this did not lead to any improvement in the patient's state. Within two days swelling appeared in the submandibular area on the left, which increased and spread to the submental and the submandibular areas on the right. The patient was hospitalized in the surgical department of the general hospital. A mandibular fracture on the left side was diagnosed that was complicated by perimaxillary phlegmon. The patient was then transferred to the specialized

department of purulent maxillofacial surgery. There, swelling and infiltration were revealed in the submandibular areas on both sides, extending to the anterior lateral surfaces of the neck and more pronounced on the left side; as well as a restriction in opening the mouth to 2 cm, infiltration and hyperemia in opening the mouth to 2 cm, infiltration and hyperemia of the mucous membrane of the left anterior palatine arch, and mobility of the fragments of the lower jaw in the left-hand corner. An x-ray examination revealed a comminuted fracture of the mandible in the area of missing teeth number 34 and number 38. The mandibular fracture line passed to the right at an oblique angle from the alveolar process of the mandible in the area of missing tooth number 38, to the hole of tooth number 34 along the edge of the mandible. There was an increase in the shade of the retropharyngeal space in the neck and mediastinum. The diagnosis was as follows: comminuted fracture of the lower jaw on the left in the area of tooth number 38; acute traumatic osteomyelitis of the lower jaw on the left; cellulitis of the floor of the mouth and submandibular spaces on both sides, the pterygomandibular and peripharyngeal spaces on the left, the anterior-lateral neck spaces; and anterior-posterior mediastinitis. It was decided to operate with general anaesthesia to open up the cellulitis of cellular tissue spaces deep in the neck. It was impossible to immobilize the jaws using splints because of the destruction of numerous dental crowns. Fiber-optic intubation proved technically very difficult to perform due to the pronounced edema of the tissues of the floor of the mouth and the pharynx. During the operation, up to 20 milliliters of fetid purulence were extracted from the floor of the mouth and the submaxillary peripharyngeal spaces. Surgical debridement of the full mouth was performed; damaged teeth 18, 16, 25, 26, 28, 48, 47 and 46 were removed. Owing to hypoxemia, the patient was kept on prolonged artificial lung ventilation in the intensive care unit. Despite treatment, the condition of the patient remained severe without improvement, and unassisted breathing could not be restored. On the patient's third day in hospital and ninth day after the injury, atonic coma due to hypoxic encephalopathy was declared. A CT scan picked up diffuse changes throughout the patient's brain tissue. On the patient's tenth day in hospital and on the seventeenth day after the injury, the patient died from progressive cardiovascular failure associated with intoxication, despite a comprehensive set of reanimation measures being applied. The postmortem diagnosis was as follows: comminuted fracture of the lower jaw on the left in the area of tooth number 38; acute traumatic osteomyelitis of the lower jaw on the left; cellulitis of the mouth floor, of the submandibular spaces on both sides, of the pterygomandibular and peripharyngeal spaces on the left and the anterior-lateral spaces of the neck; post-hypoxic syndrome. Complications included pneumothorax of the right side and intoxication. The immediate cause of the patient's death was established as cerebral edema and progressive multiple organ failure as a result of intoxication. The forensic examination of the corpse revealed multiple hemorrhages deep in the pons Varolii and the anterior third of the medulla oblongata; edema in the

fourth ventricle of cerebrum; purulent pharyngotracheitis with edema of the vocal folds; and confluent bilateral bronchopneumonia. A forensic expert qualified G.'s jaw injury as moderately severe damage to human health; however, the presence of multiple untreated foci of chronic infection in the oral cavity and delayed specialized treatment caused the development of the severe purulent complications of the fracture that determined the unfavorable progression of the trauma of the lower jaw, which led to the lethal outcome of the injury.

## 5. Conclusions

Our study confirmed when qualifying the severity of harm caused to human health, it is necessary to take into account the development of purulent-septic complications that exacerbate the progression of traumas. As well as it is mandatory to involve a maxillofacial surgeon to the work of the expert Commission in cases of qualifying the severity of harm caused to human health with injuries of the maxillofacial area and neck complicated by infectious processes. In line with the study results the factors associated with the consideration of inflammatory complications that aggravate the injury play an important role in qualifying the severity of harm caused to human health as a result of an injury accompanied by infectious processes and, therefore, in the legal assessment of the tort itself. According to the study results there is an urgent need to develop an algorithm and appropriate criteria for assessing the severity of harm caused to human health in the case of injuries to the maxillofacial area and neck injuries when these are complicated by infectious processes, as this will help bridge the gap between practical needs and the capabilities of forensic medical examination.

## References

- [1] Commentary on the Normative Legal Documents Recording the Procedure for Determining Degree of Harm to Human Health. Saint Petersburg: "Juridical Tsentr Press" Publishing House, 2008, 213 pp.
- [2] Egorova, O. Particularities in Diagnosing Mediastinitis as a Complication of Injuries to Organs of the Neck]. Institut Stomatologii, 2009, Vol. 42, No. 1, pp. 60-61.
- [3] Gubin M., V. Kulikovskiy, A. Oganesyana. Anaerobic. Non-Costridial Infection of the Face and Neck. Belgorod. 2013.
- [4] Gatterer, M., R. Toon, C. Ellestad, A. McFee, W. Rogers, J. Macj, K. Trinkle, F. Grover. Management of blunt and penetration external esophageal trauma, in: Trauma, 1985, Vol. 25, No. 8, pp. 784-792.
- [5] Govorun, I., A. Goroxov. Injuries to ENT Organs and the Neck in Peacetime and Wartime: A Guide for Doctors. Saint Petersburg: SpetsLit, 2010, 126 pp.
- [6] Klancnik M., Ivaniscevic P., Lupi-Fernandin S., Sucic A., Ledenko V., Lesin M., Krnic Martinic M., Kuscic-Juretic L. Penetrating orbitocranial injury. Acta Clinica Croatica, 2018, Vol 57, №4, pp. 792-796.
- [7] Lohiya S., Dillon J. Septic Arthritis of the Temporomandibular Joint. Unusual presentations in: Journal Oral Maxillofacial Surgery. 2016, Vol. 74, № 1. P. 87-94.
- [8] Lukosiunas A., R. Kubilius, G. Sabalis, T. Keizeris, and D. Sakavicius. An analysis of etiological factors for traumatic mandibular osteomyelitis, in: Medicina (Kaunas), 2011, Vol. 47, No. 7, pp. 380-385.
- [9] McIntyre, Robert, Gregory Van Stiegmann, Ben Eiseman. Surgical Decision Making [Russian version cited: McIntyre, Robert, Gregory Van Stiegmann, and Ben Eiseman. Surgical Decision Making Translated by Fjodorova, V. and V. Kubyschkina]. Moscow: GEOTAR-Media, 2009, 744 pp.
- [10] Popov, V., S. Skrizhinsky, O. Egorova. Particularities in Assessing Injuries to the Neck and Maxillofacial Area when Complicated by Infectious Processes, in: Forensic Medical Expertise, 2010, Vol. 53, No. 4, pp. 15-18.
- [11] Slesarenko, S., V. Agapov, V. Prelatov. Mediastinitis. Moscow: Medpraktika, 2005, 200 pp.
- [12] Trunin, M. A. Mixailov. Treatment of Neck Wounds and Injuries. Saint Petersburg: ELBI-SPB, 2004, 160 pp.
- [13] Vermel, I., M. Kovaljov, A. Khorkunov. On the Assessment of the Severity of Injuries with Infectious Complications, in: Forensic Medical Expertise, 1994, Vol. 37, No. 3, pp. 10-13.
- [14] Yakovenko L., O. Yakovenko, Gonchar D. The forensic Medical Evaluation of Injuries to the Maxillofacial Region, in: Forensic Medical Expertise, 2016. Vol. 59, № 2, pp. 10-13.
- [15] Zenger, V., A. Nasedkin, V. Parshin. Palate and Trachea Wound Surgery. Moscow: Medkniga, 2007, 364 pp.