



Methodology Article

Cancers of Oral Cavity Epidemiological and Clinical Study About 70 Cases

Garango Allaye*, Bougar Faissal, Hattab Mohammed Koussay, Kebbjaj Houda, Fawzi Saad, Mansouri Nadia Hattab

Department of Oral and Maxillo-facial Surgery, Cadi Ayyad University, Marrakech, Morocco

Email address:

allayegarango@gmail.com (G. Allaye)

*Corresponding author

To cite this article:

Garango Allaye, Bougar Faissal, Hattab Mohammed Koussay, Kebbjaj Houda, Fawzi Saad, Mansouri Nadia Hattab. Cancers of Oral Cavity Epidemiological and Clinical Study About 70 Cases. *International Journal of Clinical Oral and Maxillofacial Surgery*.

Vol. 5, No. 2, 2019, pp. 47-55. doi: 10.11648/j.ijcoms.20190502.13

Received: September 10, 2019; Accepted: October 5, 2019; Published: October 26, 2019

Abstract: Our retrospective study is about 70 cases of cancers of the Oral cavity, collected at the department of maxillo-facial surgery in Mohamed VI hospital university of Marrakech, during 9 years (January 2007-January2016). The mean age has been 60 years (20-94 years old). The women predominate with a ratio, which equal 0.94. Among the etiologic factors, tobacco is 31% of our cases and alcohol 6% of our case. Clinically, the mean delay of consultation has been 8 months. The clinical symptomatology has often consisted in the oral cavity lesions (80%), pain has been the second symptom (33%), the difficulty in swallowing and the difficulty in chewing (18%) and clinical examination showed a ulcero budding tumor in 38% of the cases, the cervical adenopathies have been noticed in 47% of the cases. The definitive diagnosis has been based on the histologic analysis that showed an epidermoid carcinoma in 87% of the cases. According to the TNM classification, the T3 are noticed in 46% and the No is found in 54%. The therapeutic strategy consisted in the surgery alone (58%), the surgery with radiotherapy (33%), the radiotherapy just (9%). Among our patients, we noticed a local recidivism in 3 cases, and we noticed two cases of metastasis, 35 patients (50%) are still a live with good carcinologic and functional result, 10 patients died; the other patients have been lost to follow-up.

Keywords: Oral Cavite, Cancer, Epidemiology, Surgery, Radiotherapy, Chemotherapy

1. Introduction

Cancers of the oral cavity represent all tumors that are born or seated in the oral cavity, with a frequency of 3% of all malignant tumors, 25 to 30% of total cancers of the airways. Upper Digestive (VADS) [1]. Oral cancer is common in men in developing countries, it is the 8th most common cancer in men and 14th in women worldwide [2]. They occur 9 times out of 10 in ethyl-tobacco subjects and very often at or near precancerous lesions [1].

In France, there are 6000 new cases per year with a strong male predominance (70% of men) [3].

The prognosis of cancers of the oral cavity is first local: local recurrence is the first cause of failure, occurring most

often in the first two years.

Early stages are curable. However, second metachronous locations are common. For advanced forms, progression-free survival, despite undeniable progress, remains below 50% at three years.

The management is multidisciplinary and involve several specialties (ENT surgeon, radiotherapist, oncologist, maxillofacial surgeon etc.).

Surgical treatment, because of its heaviness often leads to facial mutilations that have a functional and aesthetic repercussion. As a result, aesthetic damage will result in an alteration of the patient's physical appearance that undermines self-esteem as well as severe chewing, phonation and swallowing dysfunction.

2. Material and Method

This is a retrospective study on the analysis of 70 cases of oral cavity cancer, hospitalized and treated in the maxillofacial and stomatological surgery department of the Mohammed VI University Hospital of Marrakech between 2007 and 2016.

The inclusion criteria were:

- 1) Histologically confirmed oral cavity cancer.
- 2) Records of exploitable patients.

Exclusion criteria: Inoperative file.

For data analysis we used EXCEL / SPSS software.

TNM CLASSIFICATION (Our patients were classified according to the TNM classification of the International Union Against Cancer UICC 2002).

Surgical technique:

Surgery of the tumor, Lymph node dissection, Reconstruction of Substance Loss (PDS).

Non operable patients are managed by onco-radiotherapy treatment.

3. Results

3.1. Epidemiological Profile

The year 2014 is in majority of the frequency of consultation.

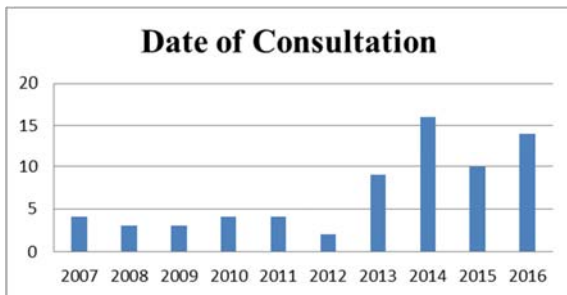


Figure 1. Distribution by year of consultation.

3.2. Age

The average age of our patients is 60 years with extremes of 20 and 94 years. The most representative age group is 60-69 years old.

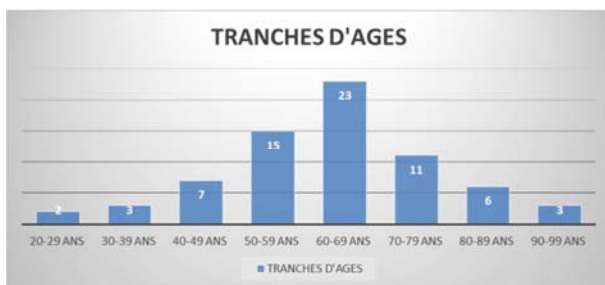


Figure 2. Distribution of patients by age group.

3.3. Sex

There were 36 female cases (51.4%) and 34 male cases

(48.6%). The sex ratio (H / F) is 0.94. Slight female predominance.

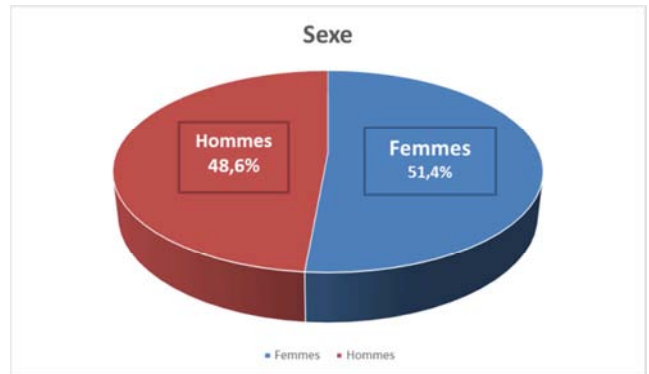


Figure 3. Distribution by sex.

3.4. The Profession

In this study, the percentage of women born to women is female at home (42.85%).

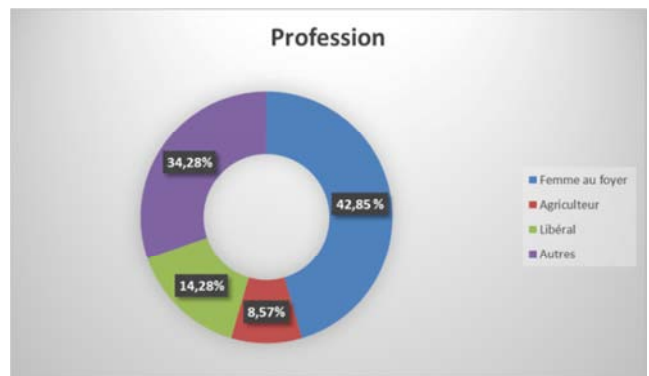


Figure 4. Distribution by occupation.

3.5. Toxic Habit

a) Smokers:

Tobacco poisoning was found in 22 patients (31%), all of them male. Consumption was about cigarettes, and it varies between 20 and 50 packs / year.

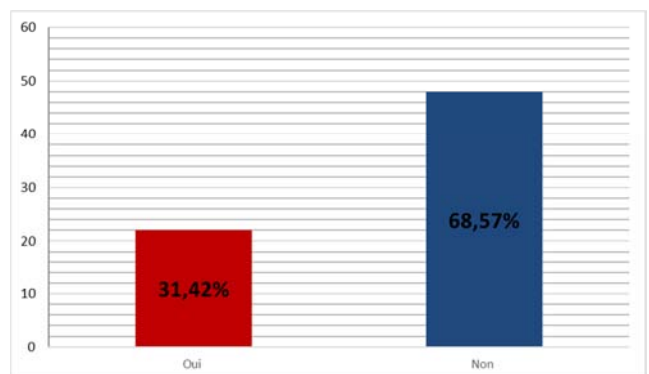


Figure 5. Distribution of smoking patients.

b) Alcoholic:

This factor was found only in 4 patients (6%), which are

all male smokers.

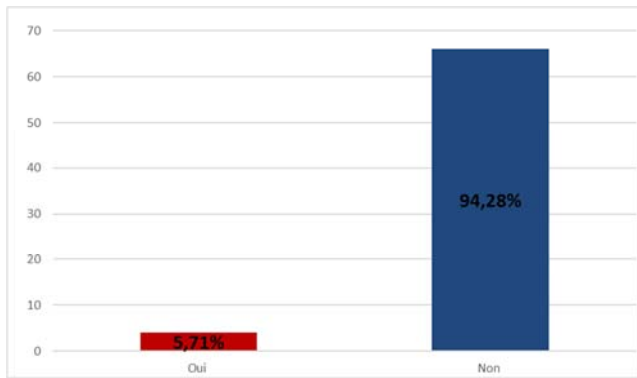


Figure 6. Distribution of alcoholic patients.

c) Poor Oral Hygiene:

Poor oral hygiene was observed in 41 patients (58.5%).

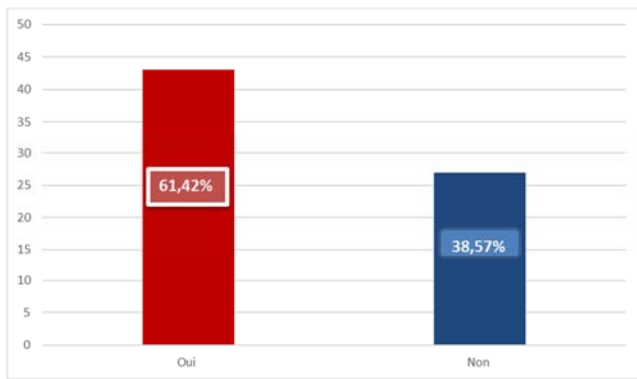


Figure 7. Distribution of patients with poor dental status.

d) Precancerous lesions:

The pre-cancerous lesions were found in 4 cases (6%): 3 cases of lingual leukoplakia and one case of erosive lichen planus.

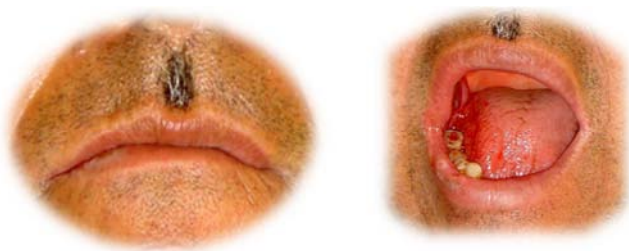

Figure 8. Lower labial squamous cell carcinoma on chronic cheilitis (service iconography).

e) Wearing of dental prosthesis: 24 patients (34%) were wearing dentures.

3.6. Clinical Data

a) Consultation time: This period was between 1 month and a half and 24 months with an average of 8 months.

b) Symptomatology of discovery:

Fifty-six patients (80%) consulted for swelling, pain was the second symptom, noted in twenty-three patients (33%),

the other symptoms were bleeding in seventeen cases (24%), functional impairment in thirteen cases (18%), the problem was aesthetic in two cases (3%).

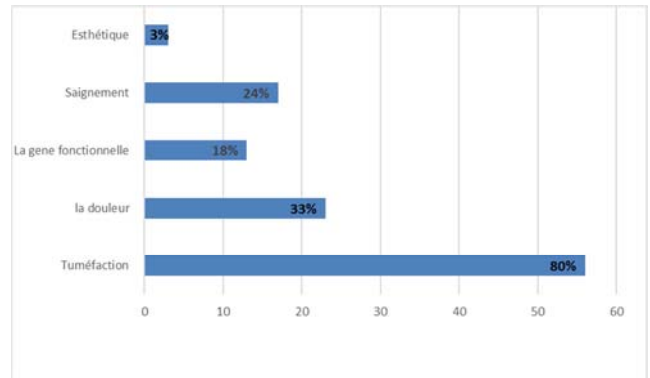


Figure 9. Consultation chart.

3.7. Physical Examination

a) Exo-oral examination:

Facial tumefaction, facial asymmetry, tumor palpation pain were recorded, In some cases there was a change in the appearance of the skin in relation to the tumor, a hypoesthesia in the territory V2 for tumors localized at the level of the tumor. maxillary and hypoesthesia for gingival-mandibular tumors.

b) Examination of the oral cavity

The ulcero-budding aspect was found in 27 cases (38%), budding in 16 cases (22%), and ulcerated in 14 cases (20%), interstitial nodule in 10 cases (14%), and ulcero-infiltrant in 03 cases (4%).

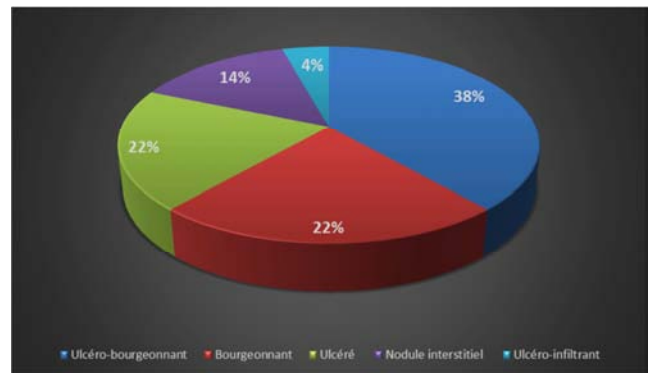


Figure 10. Macroscopic aspects.

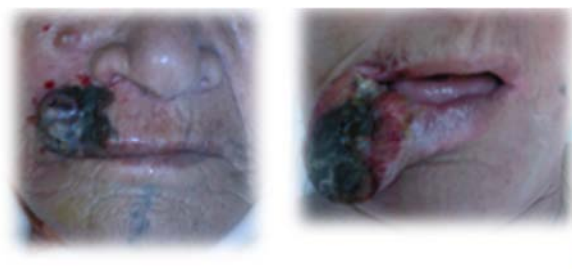

Figure 11. A: Ulcero-bleeding lesion Upper labial B: Ulcer-ulcerous lesion Right lower commissural labio.

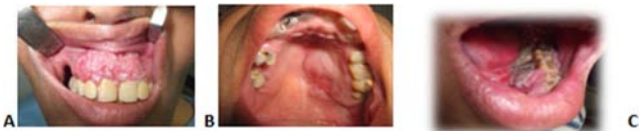

Figure 12. A: Medial maxillary gingival biliary lesion B: Left palatal nodular lesion, C: lingual lingual and vestibular gingivo ulcerative lesion.

c) Size of the tumor:

The size of the tumor was between 2 and 4cm in 35 cases (50%), less than 2cm in 18 cases (26%), and greater than 4cm in 17 cases (24%).

Table 1. Distribution according to the size of the tumor.

Size of the tumor	Numbers
2-4cm	17
<2cm	15
greater than 4 cm	38

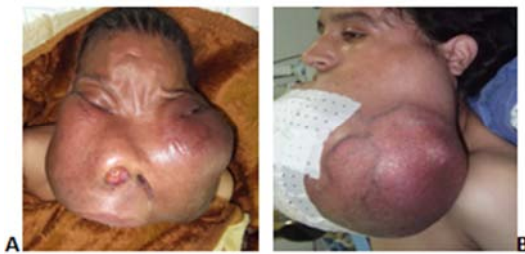

Figure 13. A: Tumor process giant pan facial type: Maxillary gingivo epidermoid carcinoma extended to the head and base of the skull (iconography of the service), B: Giant tumoral process cervico facial type: Gingivo mandibular sarcoma.

d) Siege of the tumor:

In our study, the tumor developed in the oral cavity in all cases. It was at the level of the cheek in 16 cases (23%), at the level of the tongue in 15 cases (22%), the other localizations were: the lower lip in 12 cases (17%), gingivo-labial in 11 case (16%), the upper lip in 5cas (7%), the oral floor in 6 cases (8%) and cheek and lip in 5 cases (7%).

e) Local extension:

We noted an extension to the floor of the mouth in 4 cases (6%), valleculae in 2 cases (3%), and the tonsillar lodge in 2 cases (3%).

f) Cervical examination:

We found in 33 patients (47%) palpable cervical lymphadenopathy, homolateral in 18 cases, and bilateral in 15 cases. Their seat was the jugulo-carotid area in 6 cases and the sub-mandibular area in 2 cases, not to be specified in the others.

g) Histology:

The diagnosis of cancer of the oral cavity was confirmed in all cases by histological examination of the biopsy sample taken at the level of the tumor. It revealed squamous cell carcinoma in 61 patients (87%), basal cell carcinoma in 5 cases (7%), non-Hodgkin's malignant lymphoma in 2 cases, acinar adenocarcinoma in 2 cases and verrucous carcinoma in 1 case.

3.8. Local Extension Database

a) Tomodensitometry:

The CT of the oral cavity was performed in 65 patients (93%), it objectified satellite adenopathies in 15 cases.

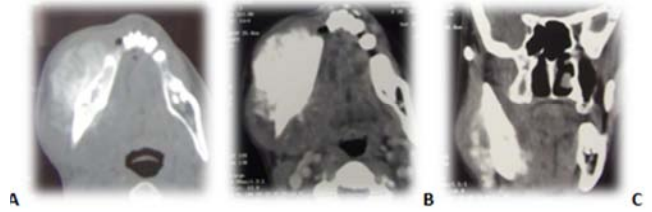


Figure 14. Facial CT: aspect of a left mandible gingivo sarcoma; A: axial view through a bony window passing through the mandible, B: axial parenchymal window cut through the mandible; C: Coronal section through parenchymal window passing through the mandible and nasal fossae.

b) Magnetic resonance imaging (MRI):

The MRI was done in 5 cases (7%), it showed an invasion of the floor of the mouth in 2 cases, the palatine tonsil in 2 cases, and satellite lymphadenopathy in 4 cases. No cases of invasion of the base of the tongue have been seen.

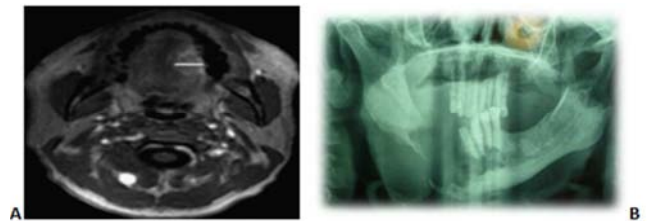


Figure 15. A: MRI in axial section, T1 sequence with gadolinium injection: Tumor of the base of the left tongue without locoregional anomaly [3], B: Panoramic dental radio showing a right lytic tumor process with rupture of the cortex and pathological fracture.

c) Orthopontomogram:

It was done in 8 patients, this examination showed signs of mandibular bone involvement in two cases.

d) Cervical ultrasound:

It was done in 5 cases (7%), it showed satellite adenopathies in all cases.

3.9. General Extension File

a) Chest X-ray: performed in all of our patients.

b) Abdominal ultrasonography: The abdominal ultrasonography was performed in 17 patients (24%), and objectified a case of liver metastasis.

c) Thoracic CT: Thoracic CT was performed in one patient and showed pulmonary metastases.

3.10. TNM Classification

We have been classified according to the TNM classification of the International Union Against Cancer UICC 2002. The results are as follows:

Table 2. Size of the tumor.

Tumor	Number of patients
T1	15
T2	17
T3	32
T4	06

Table 3. Adenopathies (ADP).

ADP	Number of patients	
N0	37	
N1	16	
N2	N2a	03
	N2b	06
	N2c	08
N3	0	

Table 4. Metastasis.

M0	68
M+	2

4. Pre-therapeutic Assessment

4.1. Clinical

The general examination assesses the general condition of the subject and looks for contraindications to general anesthesia (cardiopulmonary tare, senility and poor general condition.).

4.2. Biological

The usual biological examinations were systematically requested as a preoperative assessment: Haemogram, Rhesus group, Urea, creatinemia, Fasting blood glucose. Hemostasis report.

Two patients had type 2 diabetes balanced with oral antidiabetic drugs. They were put on transient insulin therapy before surgery.

To evaluate the operability of our patients, a chest X-ray and an electrocardiogram were routinely requested in elderly patients. A pre-anesthetic consultation was done systematically in all patients.

5. Treatment

Therapeutic protocol:

5.1. Surgery

The surgical treatment involved a local gesture and a ganglionic gesture. The surgical gesture on the tumor took into consideration the tumor size, localization as well as the locoregional extension.

Surgical treatment was recommended in 64 patients (91%). Surgical treatment consisted of: Tumor excision according to the location of the lesion

Resection of the primary tumor was associated in 58 cases with lymph node dissection:

- Unilateral functional (interesting levels I, II and III) in 32 cases (55.7%).

- Bilateral functional in 24 cases (41%).

- Radical in 2 cases (3%).

The histological study of the ganglia was systematically questioned to know whether was invaded or not. In the case of N +, the seat and the number of nodes affected, as well as the state of capsules were specified, in order to evaluate the prognosis and to adopt a possible complementary radiotherapy on the ganglion areas.

- Exeresis margin

The margin of excision was 1cm in 55 cases (86%), and 0.5cm in 5cas (8%) unspecified in the rest.

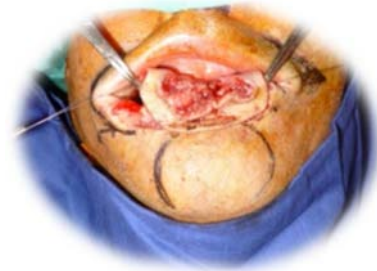

Figure 16. Lower epidermoid carcinoma labial: operative view specifying the margins of excision of the operative specimen.

- First ways:

The trans facial approach for giant tumors as the Carrega Sibileau pathway was the one used in 33 cases (51%), the way under angulo mandibular, the labio jugal approach, but also the transionic approach, all used in 31 cases (49%). Such

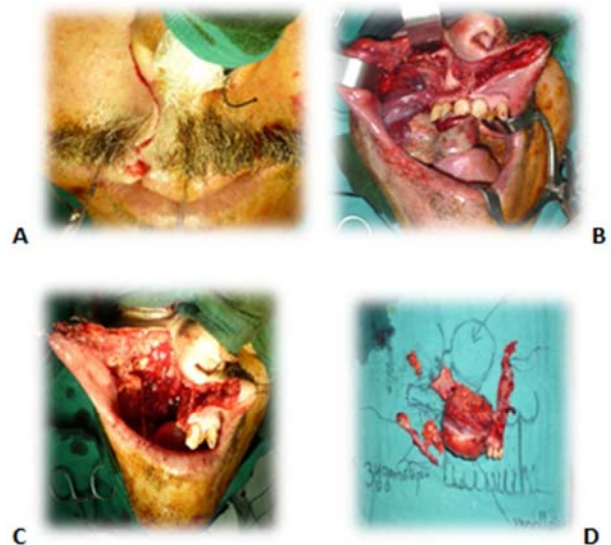


Figure 17. Operative view of the transior facial approach of the lateral nasolabial "Sébileau" modified A: to expose the deep orbito zygomatic maxillofacial borders; B: and wide excision; of the tumor process (C and D).

- Reconstruction of PDS:

Surgical treatment of lip cancer sometimes resulted in extensive loss of substance, which most often required the use of repair techniques using local or distant flaps. The reconstructions were performed at the same time after lymph node dissection and tumor resection.

The service's attitude regarding repair techniques was

influenced by the tumor location and the extent of the loss of substance. 38 patients (59%) benefited from single vicryl planar suture in 26 patients (41%) Reconstruction of the loss of substance (PDS) was done by flap:

The means used to reconstruct PDS were: Simple planar / planar sutures; Directed cicatrization; Lambeau of the pectoralis major muscle; Lambeau du Mustardé, maxi-plate + sub-mental flap; ABBE flap.

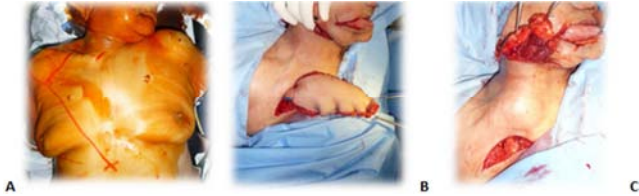

Figure 18. Pectoral Great Flap Reconstruction A: Pre-drawn drawing and cervico-thoracic facial massage, B: Flap lifting and thoraco cervico-facial tuning, C: Flap transfer to loss of substance.

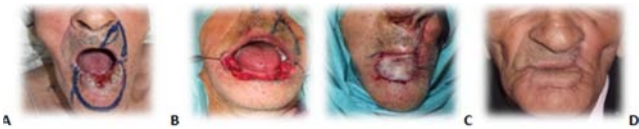

Figure 19. Lower labial reconstruction by Abbe's heterolabial flap, A: Lesional aspect of epidermoid carcinoma, B: Substantial loss of excision, C: Hetero-labial flap reconstruction Ab, D: 1-year postoperative result 'intervention.

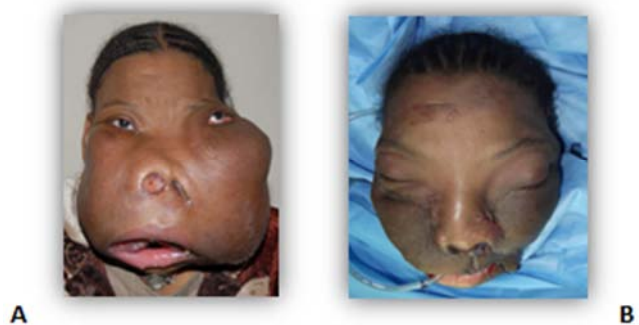

Figure 20. Panfacial maxillary gengivo carcinoma, A: Preoperative aspect, B: Intraoperative outcome after amputation.

5.2. Final Pathology

The study of the surgical specimens was performed by subsequent histological study after formalin fixation, The resection limit was healthy in 45 cases (70%) and invaded in 19 cases (30%).

Of the 58 lymph nodes achieved: 17 patients had nodal involvement (pN +) 30 patients had no nodal invasion (pN -), the rest was unspecified.

5.3. Radiotherapy

23 patients had postoperative radiotherapy at the tumor site (55 to 70 Gry) and lymph node areas (50 to 65 Gry). All these patients were classified as pN + after analysis of the operative specimens.

No brachytherapy has been done in our series, either as an exclusive or as an adjunct to external beam radiotherapy.

5.4. Chemotherapy

Only eight patients had complementary chemotherapy treatment, between them two patients had pulmonary and hepatic metastasis.

6. Evolution

Postoperative monitoring was done in the short, medium and long term with a rhythm of one consultation per month during the first semester, every three months during the second semester, every six months for two years and then once per year.

7. Recidive

Our of the twenty-three patients who were followed regularly, three presented a tumor recurrence after 6 months of treatment and radiotherapy.

A case of local recurrence for a basal cell carcinoma sclerodermiform classified T3 and Localized at the level of the upper lip.

Appearance of a second localization (of a cancer of the mobile tongue) at the level of the inner face of cheek and extended to the floor of the mouth with invasion of the base of the tongue.

A case of contralateral ganglionic recurrence for a T3 N0 tumor that had a unilateral dissection, the metastatic lymphadenopathy was contralateral. This patient was treated with external radiotherapy.

8. Survival

The average follow-up of our patients is 1 year and a half, at the end of which 35 patients (50%) are still alive without recurrence or metastases, 25 patients were lost after 1 to 5 months of follow-up, and we deplore the death of 10 patients.

9. Discussion

Oral cavity cancer is the 15th most common cancer worldwide, with more than 300,000 new cases diagnosed in 2012 (2% of all cancers). [5]

In France, [6-8] the number of new cases of cancers of the upper aerodigestive tract in 2000 is estimated at 19,600.

Oral cavity cancers rank fourth in the number of cancers of the VADS after cancers of the larynx, hypopharynx and oropharynx [9].

In Morocco [10], there is no national cancer registry. There are only two regional registers in Casablanca and Rabat and registers of private institutions.

In the five public centers: Rabat, Casablanca, Oujda, Agadir and Al Hoceima, 12,000 new cases are treated each year. At the National Institute of Oncology (INO) (Rabat), 5,300 cancer patients are treated, or 25% of the total, while the Oncology Department of Ibn Rochd (Casablanca) has 3,000.

The average age of onset of cancer of the oral cavity is 56

years for AUGUSTIN TOZOULA B [11].

AKA G AND TOURE found respectively an average age of 47.7 and 52.6 years [12, 13] For TOURE S. the most representative age group was that of the 45-54 years. Cancers of the oral cavity are observed with an average age of 45.98 years at MAGNE TAMGA DD [14].

PINSOLLE J. and COLL [15] on a series of 199 patients treated for cancers of the oral cavity and oropharynx found an average age of 60 years with extremes of 20 and 87 years.

According to PIETTE R. [16] Squamous cell carcinoma is a pathology of adults between 55 and 75 years, the average age of its occurrence is 63.7 years for women and 63.5 years for men.

For M. DIENG [17] on a ten-year study of 145 cases the average age was 52.9 years without significant difference between the two sexes. The median age of diagnosis for BARTHELEMY [18] was 60 years for men and 64 years for women.

The cancers of the oral cavity were characterized by a predominance of females in 56,20% cases for MAGNE TDD [14], these results are comparable to those of TOURE S. and MOUFTAQUIR B. which found respectively 60% and 69% of women [13,20]. Research avenues are open because, apart from the identified risk factors (tobacco, alcohol, poor oral hygiene), rational explanations can not be found. The female predominance was clearly estimated at 64.5% (sex ratio = 0.55) and concerned all age groups, AUGUSTIN T. B. [11]. The female sex was predominant for M. DIENG., with 52.9% (sex ratio = 0.8) [06].

According to the epidemiological study of PIETTE R. the man would be 1, 3 to 10 times more affected than the woman [16].

CHIDZONGA M. in his study of oral cancers in Zimbabwe found 65% of male cases [21]. In our study, we collected 36 female cases (51.4%) and 34 male cases (48.6%). The sex ratio (H / F) is 0.94. A slight feminine predominance is observed.

This female predominance can be explained by the increasing exposure of women to risk factors.

For MAGNE T. D. D. Housewives accounted for 40% of cases, followed by Farmers 15.70% of cases. [14]. Regarding the occupation of our patients, housewives in our study accounted for 42.28% of cases, followed by a liberal profession with 14.28%, then farmers in 8.57% of cases. This could be explained by the low income of these patients who consult most often at an advanced stage of the disease.

The two best-known contributing factors are tobacco and alcohol. Acting in synergy, at the origin of an increase of the risk on a multiplicative mode [22-24, 18].

Rothmann and Keller [25] specify the relationship between the intensity of smoking and the occurrence of cancer of the oral cavity: for a risk of 1 in the non-smoker, it is 1.52 if the consumption is 20 cigarettes / d and 2.43 if consumption exceeds 40 cigarettes / d.

Laurent [26], on a series of 70 patients with cancer of the mobile language between 1992 and 2002, found that 60% of patients are smokers with consumption greater than one

package per day.

FOR DIENG M. M. [17] the smoking history concerned only a small number of patients: 17% of smokers.

In the Bouyakhef series [27], smoking intoxication was found in 12 patients (33.3%), cigarette consumption varied between 18 and 50 packs / year.

In our study, smoking was found in 22 patients (31%), all of them male. Consumption was about cigarettes, and it varies between 20 and 50 packs / year.

Moderate alcohol intake (10 to 19 g / day) has little or no effect on the risk of VADS cancer in a non-smoker [5].

On the other hand, smoking habits associated with daily alcohol intake have an almost multiplying effect on the risk of developing squamous cell carcinoma of the VADS [18, 28]. Laurent [26] noted that 47% of patients had alcohol intoxication.

Bouyakhef [27] found this factor in 4 patients (11%), the same percentage observed in EL IDRISSE (11%). [29].

In our study this factor was found only in 4 patients (6%), all of whom were men and women.

Poor oral hygiene is a risk factor for cancer of the oral cavity [30, 31]. In Morocco, Bouyakhef [27] noted this factor in 80.5% of patients. Poor oral hygiene was observed in 14 patients (58.3%), with 2 patients (8.3%) totally edentulous. EL IDRISSE [32].

In our series, poor oral hygiene was observed in 41 patients (58.5%).

Precancerous lesions are tissue alterations in which the cancer appears more often than in normal homologous tissue [12]. These precancerous lesions consist of leukoplasias, erythroplaks, flat lichens and lesions caused by viruses [18, 30]. They are found in 5 to 17% of cases [27, 30, 4]. Etiologic factors in the occurrence of these lesions are tobacco, alcohol, and Human Papilloma Virus (HPV) infections [30, 4]. EL IDRISSE found these lesions in 16.6% of patients [29].

In our series, pre-cancerous lesions were found in 4 cases (6%), which is consistent with the literature.

In the literature, the average diagnosis time is 5 months [22, 1].

In Morocco, Bouyakhef [27] noted a delay of 09 months. This period was on average 6 months for EL IDRISSE [29]. For AUGUSTIN T. B. [11] this period was 18 months.

In our study series this period was between 1 month and a half and 24 months with an average of 8 months.

When the tumor is small in volume, often asymptomatic, it is fortuitously discovered by the patient himself or by the dentist at a consultation for dental care [33, 34].

Bouyakhef [27], found that the two most common tell-tale signs were swelling (55.5%) and glossodynia (25%), followed by discomfort at chewing (16.6%) and otalgia (16.6%).

Laurent [26] reported that 65% of patients had tongue ulceration, 22% of patients had localized pain in the moving tongue. 12% of patients complained of discomfort with swallowing, lingual protraction or slurred speech and 6% of patients intermittently had ipsilateral reflex otalgia at the lesion.

For EL IDRISSE [32], the most common telltale signs were

swelling (50%), ulceration (41.6%), difficulty swallowing (33.3%), discomfort with chewing (16.6%), and otalgia (16.6%). In our series of studies, 80% consulted at an advanced stage with a swelling exceeding 4cm (T3, T4) in the majority of the cases, the pain was the second symptom, noted in 33%, the other symptoms were functional impairment in 18%, bleeding at was present in 24%.

The budding ulcer form is the most common form of cancer of the oral cavity [4]. For EL IDRISSE [32], the aspects found were: the ulcero-budding aspect (50%), budding (25%), and ulcerated (25%).

In our study series, the ulcero-budding appearance was found in 38%, budding in 22%, and ulcerated in 20%, interstitial nodule in 14%, ulcer-infiltrant in 4%.

Combined inspection and palpation can be used to quantify the size and volume of the lesion at the level of the tongue, lips, inner side of the cheeks, also at the level of neighboring structures [1].

Aksu [35] found that 70% of patients had tumors <4 cm.

For EL IDRISSE [19], the size of the tumor was between 2 and 4 cm in 58.3% of cases.

In our study series, the size of the tumor exceeds 4cm in 54%, less than 2cm in 22%, and between 2 and 4cm in 24%.

AUGUSTIN T. [11], tongue cancers were the most common 32.1%, followed by cancer of the palate 25% and cancers of the cheek 21.4%.

M. DIENG [17], the mobile tongue and the inner side of the cheeks were elective topographies for cancer.

MAGNE M. T. D. [14] observed a predominance of palate and tongue in 33.3% and 25% of cases.

CHIDZONGA M. and YOUNES Y. found respectively a prevalence in the tongue in 20.50% and 38% of cases [21,36].

AKA G noted 24% in the tongue and 10.10% in the palate [12]. TOURE S. and Coll reported 21.90% at the level of the tongue and 14.30% at the level of the palate [13].

However according to PIETTE R., the preferential localization of oral tumors is in 50% of cases in the mobile tongue and the floor of the mouth [16].

In our study, the tumor developed in the oral cavity in all cases. Lip dominance was observed in 17 cases (24%), the inner side of the cheek in 16 cases (23%), in the tongue in 15 cases (22%).

Our results are comparable to those found in the literature; this is because tobacco and alcohol act electively on the mobile tongue, but in reality all parts of the oral mucosa may be involved.

The 5-year survival rate is > 80% and can reach 96.7% [39, 40].

Zhien [41], on a series of 229 T1T2N0, found a specific survival rate at 5 years at 79% for patients who had undergone tumor surgery with lymph node dissection versus 62% for those who underwent tumor surgery alone.

In a series of T2 tumors, the 5-year survival was 61% for patients treated by surgery, supplemented by radiotherapy, compared with 53% for those treated with exclusive brachytherapy [22].

This rate was difficult to estimate in our study as 36% of our patients were lost to follow-up.

10. Conclusion

Cancers of the oral cavity represent a real problem of public health in Morocco. Their profile of giant tumors and lymphophiles found at an advanced stage explains the complexity of the management and the severity of the prognosis

These cancers are common in Morocco, they are the most frequent of the upper aerodigestive tract. They occur mostly in elderly female subjects with a sex ratio = 0.94. Any suspicious lesion of the oral cavity requires a biopsy and histopathological examination for squamous cell carcinoma, the most common form.

Any isolated cervical lymphadenopathy seen in adults should seek cancer of the oral cavity.

The management of cancers of the oral cavity is multidisciplinary (surgery, radiotherapy, chemotherapy) to improve the survival expectancy of the patient.

Oral cavity cancers diagnosed at an advanced stage require mutilating surgery with sometimes complex reconstruction processes, hence the interest of early diagnosis.

Regular short- and long-term monitoring of patients is essential.

Conflicts of Interest

The authors declare no conflict of interest.

Contributions of the Authors

All the authors contributed to the realization of this work, all have read and approved the final version of this manuscript.

References

- [1] Augustint., Mathiew M., Tarcissus K., Hierrhum Aboubacar b., Dieudonne O, Simon T: Les cancers de la cavité buccale: affection à prédominance féminine à Ouagadougou Med Buccale Chir Buccale 2015; 21: 61-66.
- [2] Aka Gblanh K. F. P: Les tumeurs malignes bucco-maxillo-faciales: étude statistique thérapeutique: à propos de 119 cas: Thèse de médecine 1163 N° 91/Abidjan.
- [3] Magne Tanga Denise Diane: Etude épidémiologique et histopathologique des cancers stomatologique et maxillo-faciaux: à propos de 70 cas: Thèse en médecine dentaire 2007/Mali.
- [4] Barthelemy, Sannajust J., P., Mondie J. M: Cancers de la cavité buccale: Préambule, épidémiologie, étude clinique EMC-Stomatologie 1 (2005) 277-294.
- [5] M. M. Dieng, A. Dem, P. M Gaye, D. Diouf, S. Toure, R. Diop, M. Ndiaye, B. Loum: Cancers de la cavité buccale: à propos de 145 cas à l'institut joliot-curie de Dakar Posters/ Cancer/Radiothérapie 16 (2012) 524-581.
- [6] Thariat J: Évolution des concepts dans les cancers des voies aérodigestives supérieures. Bull Cancer 2013; 100: 983-97.
- [7] Prades J. M., Shmitt T., Timoshenko A: Cancers de la langue. EMC, ORL 1, 2004. P. 35-55.

- [8] Crissman JD, Sakrwa: Squamous neoplasia of the upper aerodigestive tract. Intraepithelial and invasive squamous cell carcinoma. In: Head and neck Surgical pathology, Pilch BZ. Philadelphia, Lippincott Williams & Wilkins 2001: p 34-52.
- [9] Szpirglas H., Guilbert F: Cancers de la cavité buccale. Préambule. Encycl Méd Chir (Elsevier SAS, Paris), (stomatologie, 22-063-A-05), 1996.
- [10] Ferlay J, Steliarova-Foucher E, Lortet-Tieulent J, et AL: Cancer incidence and mortality patterns in Europe: Estimates for countries in 2012. *European Journal of Cancer* (2013) 49, 1374-1403.
- [11] Centre International de Recherche sur le Cancer: Communiqué de presse N° 164: OMS 3 Juin 2005.
- [12] Brugere J: Les cancers des VADS la ligue nationale contre le cancer. *Bulletin* Novembre 2002 15 p.
- [13] Gnepp DR. *Diagnostic Surgical Pathology of the head and neck*: Philadelphia, Sanders ed, 2000, 888 pages.
- [14] Rodrigues P. C, Miguel M. C. C, Bagordakis E. and al: Clinicopathological prognostic factors of oral tongue squamous cell carcinoma: a retrospective study of 202 cases. *Int. J. Oral maxillofac. Surg.* 2014; 43: 795-801.
- [15] A. Auperin, C. Hill: Epidémiologie des carcinomes des voies aérodigestives supérieures *Cancer/Radiothérapie* 9 (2005) 1-7.
- [16] Remonter L., Buemi A, Velten M., Jouglà E., Esteve J: Evolution de l'incidence et de la mortalité par cancer en France de 1978 à 2000. Saint-Maurice: Institut de veille sanitaire; 2003.
- [17] Hill C: Epidemiology of cancer of upper aerodigestive tract. *Bull cancer* 2000; 5 (suppl): 5-8.
- [18] Rothman K., Keller A: The effect of joint exposure to alcohol and tobacco on risk of the mouth and the pharynx. *J Chronic Dis* 1972; 25: 711-6.
- [19] Laurent B: Cancer de la langue mobile: facteurs pronostiques des carcinomes épidermoïdes T1-T2 de la langue mobile. Thèse médicale Nantes, 2006.
- [20] Bouyakhlef M: Cancers de la langue mobile. Thèse de médecine N° 214, 2002, Casablanca.
- [21] Eisenberg E: Oral lichen planus: A benign lesion. *J Oral Maxillofac surg* 2000; 58: 1278-1285.
- [22] Buisset E, Leferbe JL, et al: Les cancers linguaux et pelvi-lingaux: valeur pronostique de l'envahissement anglionnaire. A propos de 744 cas. *Ann Oto-laryngol Chir Cervicofac* 1989; 106, 8: 551-555.
- [23] Manual, *Cancer Staging Handbook from the AJCC Cancer Staging*: New York: Springer-Verlag: 2002.
- [24] Barnes L, Eveson JW, Reichart P, Sidransky D: World Health Organization international classification. Pathology and genetics of Head and Neck tumors. Lyon, IARC Press, 2005, 430 pages.
- [25] Piette R: *Traité de pathologie buccale et maxilla-faciale*. Université de Bruxelles 1991, P 502-511.
- [26] Pinsolle J., Demeaux H., Coustal B., Siberchicot f, Caudry M., Maitre J. P., Michelet f. X: Results of surgical treatment of T3 and T4 tumors of the oral cavity and oropharynx. *Am. J. Surg.* 1992, 164: 587-91.
- [27] Menegoz F., Lesch JM., Rame JP., Reyt e. Bauvin E., Areveux P, et al: Les cancers de la lèvre, de la cavité buccale et du pharynx en France: incidence, mortalité et tendance (période 1975-1995). *Bull Cancer* 2002; 89: 419-429.
- [28] Lebeau J: Cancer du plancher buccal, des joues, des lèvres, de la voûte palatine et des gencives. *Rev du praticien* 40-33. Paris 1990.
- [29] Toure S., Sonko L., Diallo B. K., Diop A: Profil épidémiologique des cancers de la cavité buccale au Sénégal. *Revue de stomatologie et de chirurgie maxillo-faciale* Vol 106- N° SUP 4- Septembre 2005, P 68, Masson, Paris, 2005.
- [30] Gehanno P, Baillet F, Brujer J, et al: Cancers de la langue. *Encycl Méd Chir Oto-Rhino-Laryngologie* 1995; 20-627-A-10: 12 p.
- [31] Pinsolle J, Mauruc B: Cancer de la langue: étiologie, diagnostic, évolution et pronostic, principes du traitement *Rev Prat* 1990; 40, 19: 1811-1814.
- [32] Aksu G. et al: Treatment results and prognostic factors in oral tongue cancer: analysis of 80 Patients. *Int. J. Oral maxillofac. Surg.* 2006; 35: 506-513.
- [33] Azerad J: *La physiologie de la mastication*. Paris: Masson 1992-175 p.
- [34] Younes Y: Les cancers de la cavité buccale: à propos de 256 cas. Thèse Med.: Dakar 1996, N° 33.
- [35] Robbins KT, Clayman G, Levine PA, Medina J, Sessions R, Shaha A, et al: Neck dissection classification update: revisions proposed by the American Head and Neck Society and the American Academy of Otolaryngology-Head and Neck Surgery. *Arch Otolaryngol Head* 2002, 128: 751-8.
- [36] Pevél D, Marc R: *Précis d'audiophonologie et de déglutition*. Tome II. Les voies aéro digestives supérieures. Marseille; 2009; p. 54.
- [37] Perrinaud A: Carcinomes épidermoïdes. *Presse Med.* 2008; 37: 1485-9.
- [38] Mazon JJ. Et al: Cancer de la langue mobile. *Le concours médical* 1988; 110, 44: 4051.