



Case Report

Fibrolipoma of the Floor of the Mouth and Submandibular Space: A Rare Clinical Entity

Aliyu Daniel^{1,*}, Sahabi Saddiku Malami², Zubairu Musa Yauri³, Adeyeye Foluso Mercy¹

¹Department of Ear, Nose and Throat, Usmanu Danfodiyo University Teaching Hospital, Sokoto, Nigeria

²Department of Histopathology, Usmanu Danfodiyo University Teaching Hospital, Sokoto, Nigeria

³Department of Otorhinolaryngology, Sir Yahaya Specialist Hospital, Birnin Kebbi, Nigeria

Email address:

danoaliyu@yahoo.com (A. Daniel)

*Corresponding author

To cite this article:

Aliyu Daniel, Sahabi Saddiku Malami, Zubairu Musa Yauri, Adeyeye Foluso Mercy. Fibrolipoma of the Floor of the Mouth and Submandibular Space: A Rare Clinical Entity. *International Journal of Clinical Oral and Maxillofacial Surgery*. Vol. 5, No. 1, 2019, pp. 10-13. doi: 10.11648/j.ijcoms.20190501.13

Received: June 26, 2018; Accepted: March 14, 2019; Published: April 8, 2019

Abstract: Lipoma is a benign soft tissue tumour of mature adipose tissue and are observed as slow growing, painless, and asymptomatic masses. Occurrence in the submandibular space is relatively rare. We report a case of an unusually huge and plunging fibrolipoma of the floor of the mouth and submandibular space. We report a 52 years old housewife with complaint of progressive painless swelling of the floor of the mouth and submandibular space with interference to speech and mastication for 3years. Clinical examination revealed an 8cm mobile lobulated mass in the floor of the mouth and plunging into the left submandibular space with no ulceration or signs of inflammation on the overlying mucosa. A needle aspirate of the mass yielded no fluid. Ultrasonography revealed a lobulated extra-oral mass. The lesion was subsequently excised under general anesthesia and histopathological analysis of the tissue showed lobules of mature adipocytes admixed with fibrous tissues, which confirmed the diagnosis. Fibrolipoma of the floor of the mouth and submandibular space is an uncommon tumour with good prognosis. Complete surgical excision is the treatment of choice. Histopathological examination of the tissue must be performed to confirm diagnosis.

Keywords: Fibrolipoma, Mouth, Submandibular Space, Adipocytes

1. Introduction

Lipomas are benign soft tissue tumor of mature adipose tissue, one of the most common benign neoplasms encountered, affecting the trunk region, shoulders, upper arms, neck and gastrointestinal tract [1]. They rarely affect the oral cavity, however, it account for 1 to 4% of all benign neoplasms of the oral cavity [2, 3]. Lipomas may be seen to affect the submandibular space, lips, tongue, palate, floor of the mouth and vestibule [4]. There are various histological variants of lipomas namely fibrolipomas, spindle lipomas, intramuscular lipomas, angiolipomas, salivary gland lipomas, pleomorphic lipomas, myxoid lipomas and atypical lipomas [5, 6].

Fibrolipomas are slow growing, encapsulated, longstanding, painless soft tissue swellings which are either superficial or

more deeply located and covered by normal mucosa [1, 2, 7]. They may affect superficial or deep tissues of the oral cavity, lips, tongue, palate, floor of the mouth and constitute the most prevalent variant of the histologic type according to World Health Organization [8]. Majority of patients affected are 40 years and above [1, 9]. Fibrolipomas are a rare variant with fats cells embedded within dense connective tissues [6, 8]. Although it has an uncertain etiology and pathogenesis, inflammatory, endocrine imbalance and mechanical influences are being implicated in its development. An anomalous localization of fatty tissues or an alteration in the lipid metabolism of the tongue has been reported. It is believed that fatty tissue proliferation is often triggered following mild trauma [9]. The clinical pattern of other variants is similar to that of fibrolipoma, hence many

differential diagnoses can be elucidated. It is believed that patient commonly seek medical attention only when they experienced difficulties in swallowing, phonation and mastication due to significant increase in size of the tumor. Recurrence post-surgical excision is rare; hence have excellent prognosis [10, 11].

2. Case Report

We present a 52-year-old housewife referred to a tertiary health Centre in north western Nigeria, with complaint of progressive painless swelling on the neck (figure 1) and floor of the mouth interfering with speech and positive history of difficulty in mastication for 3 years. Clinical examination revealed a 8cm x 4cm mobile lobulated, well defined mass in the floor of the mouth and plunging into the left submandibular space (figure 2). There were no signs of ulceration or inflammation on the overlying mucosa. The mass was slippery, non-tender, and soft. A provisional diagnosis of plunging ranula was entertained.

Ultrasonography revealed a lobulated extra-oral mass and needle aspirate of the mass yielded no fluid. Routine blood investigations were within normal limit. The lesion was subsequently resected under general anesthesia (figure 3) and histopathological analysis of the tissue revealed lobules of mature adipocytes admixed with fibrous tissues (figure 4), which confirmed a diagnosis of fibrolipoma. One-week post excision was uneventful (figure 5).

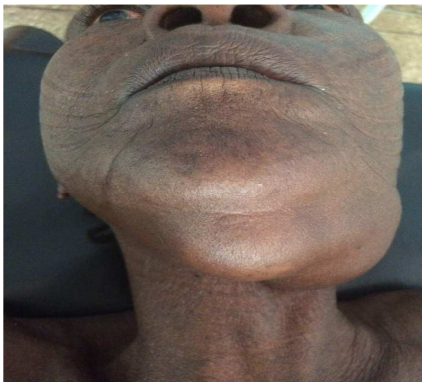


Figure 1. Clinical photograph showing fibrolipoma of the floor of the mouth presenting as left submandibular swelling.

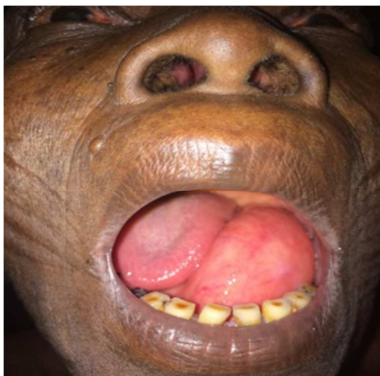


Figure 2. Clinical photograph of huge intraoral mass affecting deglutition. The Tongue displaced contralaterally.

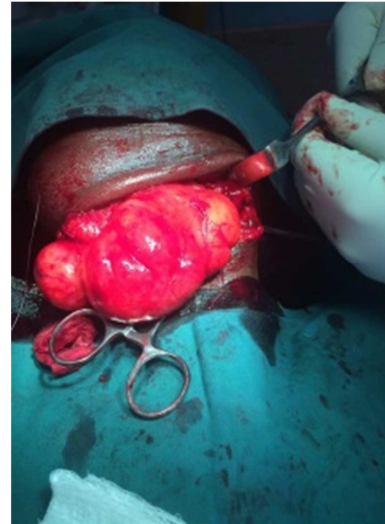


Figure 3. Intraoperative excision of fibrolipoma.

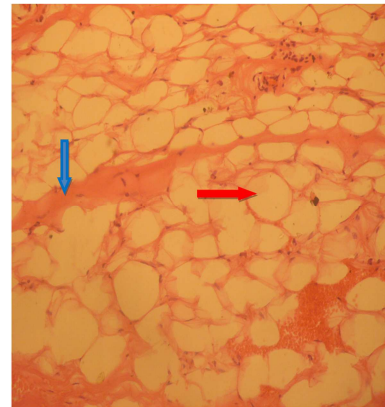


Figure 4. Photomicrograph of fibrolipoma composed of lobules of mature adipocytes (red arrow) admixed with fibrous tissue (blue arrow). H&E Mag. x200.

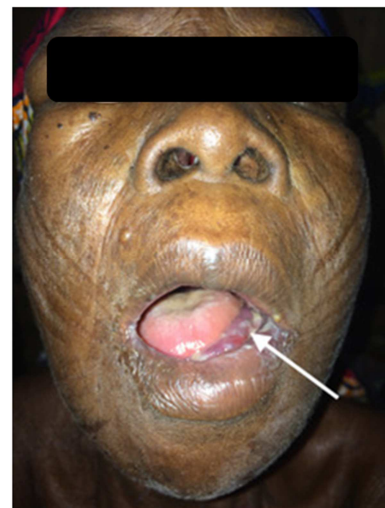


Figure 5. Seven days post excision of the oral component of the mass shown by the arrow as Compared with figure 2.

3. Discussion

Lipoma is a very frequent benign tumor of adipose tissues

[1]. Roux first described it in 1848 as 'yellow epulis' [12]. The world Health Organisation (WHO) classifies Lipoma histologically in to: Conventional lipomas, angiolipomas, pleomorphic lipomas/spindle cell, fibrolipomas, mixolipomas, condrolipomas, osteolipomas, lipomatosis, lipomatosis of the nerve, hybernomas and lipoblastomas [2]. Fibrolipomas, a microscopic variant of lipoma is rare as compared to conventional lipoma; few cases are seen in the oral cavity [13]. They appear as pink shiny oval shaped masses with variable volume and dimensions, slow growing, painless and are distinctively separate from surrounding tissues. The mature fat cells composition of fibrolipoma is mostly subdivided into lobules by fibrous connective tissues from where multiple fibrous bands originate which often adhere to adjacent structures with focally pseudo-infiltrating pattern mimicking a malignant infiltrating tumour. They occur rarely in children and more common in males than females [14] though de Freitas [15] reported a higher female predilection. Most patients present to a medical facility after several years of onset mainly because of cosmesis and functional deficit [16, 17]. The tumor though benign may be life threatening due to upper airway obstruction and may be a cause of difficult intubation [18]. Preliminary diagnosis is made by history and physical examination. The pathogenesis of fibrolipomas are uncertain [19] however fatty degeneration, hormonal basis, trauma, infection, infarction, metaphase of muscle cells, lipoblastic embryonic cell nest in origin and chronic irritation are some theories to describe the formation of a lipoma [20]. An anomalous localization of fatty tissues or an alteration in the lipid metabolism of the tongue has been reported. It is believed that fatty tissue proliferation is often triggered following mild trauma. Fibrolipoma is a histologic variant with fat cells entrapped in dense collagen network and grossly are encapsulated tumors [21]. Diagnosis of fibrolipoma is made based on clinical presentation and histological findings [13, 14]. They are generally asymptomatic although mastication, swallowing and phonation dysfunction has been reported due to the space they occupy. The tumor though benign may be life threatening due to upper airway obstruction. Imaging studies such as computed tomographic scan (CTscan) and ultrasonography has been found useful due to complexity of differential diagnosis. Although diagnostic fine needle aspiration cytology is useful but in many cases it is not adequate enough to confirm the diagnosis of fibrolipoma. Fibrolipoma of the mouth can be mistaken for a malignant infiltrating lesion due to its histologic characteristics and focal pseudo-infiltration of surrounding tissues. D'Antonio et al. described the case of a woman affected by a pleomorphic lipoma of the tongue simulating a liposarcoma [22]. These make histological examination compulsory for accurate diagnosis. Treatment is by complete surgical excision [9, 14, 20]. Fibrolipomas have excellent prognosis.

4. Conclusion

Fibrolipoma of the floor of the mouth and submandibular space is an uncommon tumour with good prognosis. It can be

mistaken for a malignant infiltrating lesion due to its histologic characteristics and focal pseudo-infiltration of surrounding tissues. Such as liposarcoma. Complete surgical excision is the treatment of choice. Histopathological examination of the tissue should be performed to confirm diagnosis.

References

- [1] Furlong MA, Fanburg-Smith JC, Childers EL. Lipoma of the oral and maxillofacial region: Site and subclassification of 125 cases. *Oral Surgery, Oral Medicine, Oral Pathology, Oral Radiology, and Endodontology*. 2004 Oct 31; 98(4): 441-450.
- [2] Fregnani ER, Pires FR, Falzoni R, Lopes MA, Vargas PA. Lipomas of the oral cavity: clinical findings, histological classification and proliferative activity of 46 cases. *International journal of oral and maxillofacial surgery*. 2003 Feb 1; 32(1): 49-53.
- [3] Vinod SV, George A, Thomas N, Paulose DE, Joy A. Oral lipoma: Report of two cases with different clinical appearance and review. *Journal of Dental and Medical Sciences*. 2016; 15(3):120- 124.
- [4] Trandafir D, Gogălniceanu D, Trandafir V, Căruntu ID. Lipomas of the oral cavity--a retrospective study. *Revista medico-chirurgicala a Societatii de Medici si Naturalisti din Iasi*. 2007; 111(3): 754.
- [5] Woolgar JA, Hall GL. Benign tumours of the mouth and jaw. *Stell & Maran's Textbook of Head and Neck Surgery and Oncology*. 2011 Dec 30: 239.
- [6] Vadvadgi VH, Saini R. Oral Fibrolipoma of Oral Cavity. *International Journal of Experimental Dental Science*. 2014 Jul 1; 3(2): 106.
- [7] Iwase M, Saida N, Tanaka Y. Fibrolipoma of the buccal mucosa: A case report and review of the literature. *Case Reports in Pathology*. 2016; 4:1-4.
- [8] Pereira T, Shetty S, Sapdhare S, Tamgadge A. Oral fibrolipoma: a rare histological variant. *Indian Journal of Dental Research*. 2014 Sep 1; 25(5): 672.
- [9] Ghanchi M, Bhakar V, Saxena K, Jani D. Fibrolipoma of the oral mucosa: A review of literature. *Sch. J. Dent. Sci*. 2016; 3(9): 269-271.
- [10] Giorgio I, Marco F, Atirge C, Antonio R, Giovanni DO, Luigi C. Rare fibrolipoma of the tongue: A case report. *Journal of Medical Case Reports*. 2015; 9:177-181.
- [11] Gupta S, Pathak S. Fibrolipoma of buccal mucosa-a case report. *J Indian Dent Assoc*. 2011; 5: 737-738.
- [12] Rehani S, Bishen KA. Intraoral fibrolipoma-a case report with review of literature. *IJDA*. 2010 Apr 1; 2(2): 215-216.
- [13] Roux M. On exostoses: their character. *Am J Dent Sci*. 1848; 9:133-4.
- [14] Manjunatha BS, Pateel GD, Shah V. Oral fibrolipoma-a rare histological entity: report of 3 cases and review of literature. *Journal of dentistry (Tehran, Iran)*. 2010; 7(4):226.

- [15] Janas A, Grzesiak-Janias G. The rare occurrence of fibrolipomas. *Otolaryngologia polska= The Polish otolaryngology*. 2005; 59(6):895-8.
- [16] De Freitas MA, Freitas VS, de Lima AA, Bastos Pereira J, Nunes dos Santos J. Intraoral lipomas: A study of 26 cases in a Brazilian population. *Quintessence International*. 2009 Jan 1; 40(1).
- [17] Rajeev R, Beena VT, Indu G, Choudhary K, Devu A. Fibrolipoma of floor of the mouth of 20 years of duration. *Clinical Cancer Investigation Journal*. 2014 Sep 1; 3(5):394.
- [18] Khubchandani M, Thosar NR, Bahadure RN, Baliga MS, Gaikwad RN. Fibrolipoma of buccal mucosa. *Contemporary clinical dentistry*. 2012 Apr; 3(Suppl1): S112.
- [19] Rimmer J, Singh A, Irving C, Archer DJ, Evans PR. Asymptomatic oropharyngeal lipoma complicating intubation. *The Journal of Laryngology & Otology*. 2005 Jun; 119(6):483-5.
- [20] Chikui T, Yonetsu K, Yoshiura K, Miwa K, Kanda S, Ozeki S, Shinohara M. Imaging findings of lipomas in the orofacial region with CT, US, and MRI. *Oral Surgery, Oral Medicine, Oral Pathology, Oral Radiology, and Endodontology*. 1997 Jul 1; 84(1):88-95.
- [21] Bajpai M, Chandolia B, Arora M. Angiomyxolipoma of tongue. *J Coll Physicians Surg Pak*. 2017; 27(4):252-253.
- [22] Woolgar JA, Hall GL Benign Tumours of the Mouth and Jaw. In: Stell and Maran's textbook of Head and Neck Surgery and Oncology (Watkinson JC, Gilbert RW, editors). 5th edition, Hodder and Stoughton, UK. 2012, 239-55.
- [23] D'Antonio A, Locatelli G, Liguori G, Addesso M. Pleomorphic lipoma of the tongue as potential mimic of liposarcoma. *J Cutan Aesthet Surg*. 2013; 6:51-3. Doi: 10.4103/0974-2077.110101.