



Risks and Complications in Patients with Oral Cancer

Otto Alemán Miranda

General Clinical and Surgical, Hospital Orlando Pantoja Tamayo, Santiago de Cuba, Cuba

Email address:

Ottoaleman92@gmail.com

To cite this article:

Otto Alemán Miranda. Risks and Complications in Patients with Oral Cancer. *International Journal of Clinical Oral and Maxillofacial Surgery*. Vol. 8, No. 1, 2022, pp. 8-15. doi: 10.11648/j.ijcoms.20220801.13

Received: May 12, 2022; Accepted: May 27, 2022; Published: May 31, 2022

Abstract: Oral cancer is a multifactorial disease of unknown origin, which affects millions of people in the world. Its attention and treatment must be carried out in multidisciplinary teams, since it becomes complex for the dental professional to carry out its management independently. This motivated the realization of the present investigation with the objective of describing the main risks and complications in patients with oral cancer. To do this, an exhaustive bibliographic review was carried out based on national and international literature, using different descriptors in English and Spanish. The previous experience of the author was taken into account. Then a critical analysis was carried out, where the main risks and complications that can occur in these patients were compiled. Dissimilar conditions and the scope of the therapeutic procedures carried out in these patients with oral cancer were illustrated. The content was organized by anatomical regions and surgical treatments. It exposes in a structured and schematic way several of the complications that can occur in these procedures. At the end of the investigation, it is concluded that there are multiple complications and risks to which these patients are exposed, causing functional, mechanical, aesthetic, psychological and nutritional alterations.

Keywords: Oral Cancer, Risks, Complication, Head and Neck

1. Introduction

In this century, orofacial cancer continues more than ever to be a challenge for all professionals who, directly or indirectly, participate and collaborate in this sacrificial work, dedicated to saving those who suffer from it. [1].

Stomatology is the one with the greatest responsibility, the doctors of the different stomatological specialties play important roles in the multidisciplinary team that provides care to those affected by Head and Neck cancer.

There are three main oncospecific treatments used in the buccocervicofacial regions, which are first-line surgery, followed by radiotherapy and chemotherapy. Whatever is prescribed, the Stomatologist must collaborate in the pre and postoperative period, and in certain cases even in the intraoperative period. [1-3].

Always trying to detect, prior to oncological treatment, different oral conditions that may be present before oncospecific therapy. Carrying out your treatment and thus avoid complications or sequelae of said treatments or at least reduce their severity. The main reason for dental treatment prior to cancer treatment is to avoid oral infections that can be

the starting point of serious systemic conditions.

Oral cancer is an international health problem, so it is essential that professionals master this subject.

The above raised led us to carry out the present investigation.

1.1. Objective

Describe the main risks and complications of oral cancer and its surgical treatments.

1.2. Reference Search Methods

The scientific information was compiled through a search using the following descriptors in English: the Medical Subject Headings (MeSH): “oral cancer, oral cavity carcinoma, Risks, Complication, Head and Neck.

1.3. Analysis Strategy

The search was based solely on oral cancer and complications and risk factors in these patients.

2. Development

2.1. Stomatological Indications Prior to Oncospecific Treatments

- 1) Caries, pulpal and periapical infections of dental origin should be removed 14-21 days before the start of cancer therapy to ensure a correct period of healing and periapical scarring.
- 2) Endodontic therapy must be completed at least 14 days prior to initiation of cancer therapy.
- 3) Those radiolucent periapical lesions in endodontically treated teeth should be retracted, performed apicoectomy or extracted, since they could well be lesions where defense and aggression are in balance but when the patient is immunocompromised the process would worsen. [1-3].
- 4) A deep scaling should also be done.
- 5) Periodontal surgery is not advised because the periodontium is the most common site of initiation of oral and systemic infection.
- 6) teeth with unfavorable pulpal or periodontal prognosis (expectancy less than one year for those in the mouth) should be extracted.
- 7) Retained teeth and those within the irradiation zone should also be extracted.
- 8) For extractions, the following guidelines must be followed: use a technique that is as atraumatic as possible, strictly aseptic, perform alveoloplasty if necessary and bone regularization, achieve closure by first intention, leaving 14-21 days for complete healing and periodic control of the same.
- 9) Before carrying out the extractions, it is necessary to keep in mind what the oral prosthetic or bucco-maxillofacial rehabilitation treatment is going to be, to take into account the dental anchorages.
- 10) If there is a dental implant in the irradiation field, it is up to professional judgment to remove it or not, since metals are known to cause radiation overdose in their area and reduce it in underlying areas.
- 11) Poorly fitting prosthetic devices can traumatize the oral mucosa and increase the risk of microbial invasion.
- 12) Prostheses should be evaluated and adjusted as necessary to reduce the risk of trauma, and it should be remembered that during cancer treatment they should only be used for feeding.
- 13) Conventional X-rays of the parts to be treated and panoramic should be taken at the beginning of the treatment.
- 14) Then clinical and radiological control should be done every six months to evaluate the state of the restorations, possible recurrence of pulpal and/or periapical pathologies.
- 15) At this stage, the patient's oral hygiene should be assessed and a systematic and complete oral hygiene routine established by mutual agreement. [2-4].
- 16) Oral hygiene.
- 17) It is important to inform the patient that in the course of treatment of an oncological disease, systemic infections often develop, many of them originating in the buccomaxillary sphere, which are eventually fatal.
- 18) Oral hygiene should be performed with a straight handle brush, soft nylon bristles with 2 or 3 rows, three to four times a day with the Bass method modified for cleaning the gingival sulcus, including the dorsal aspect of the tongue and rinsing the mouth. frequently so that no traces of toothpaste remain.
- 19) Pastes with a concentration of 1450 ppm of fluoride, or higher concentration, should be used. As the flavors used in the paste can irritate the oral soft tissues, use of a paste that is relatively neutral in taste should be considered. [4-6].
- 20) Rinsing the brush in hot water every 15 to 30 seconds during brushing softens the brush and reduces the risk of trauma.
- 21) The brush should be air-dried between each use to avoid contamination and bacterial colonization, which would make it an infectious vector, and should be changed every 2-3 months or when its bristles lose shape and/or bend.
- 22) When the use of a regular toothbrush is not possible, a possible alternative (although less effective) is the use of a foam toothbrush and fluorinated gel. Hygiene should also be complemented with non-sugar and alcohol-free antimicrobial rinses, reminding the patient that these are only auxiliary chemical means and that mechanical plaque removal is very important and more effective.
- 23) These rinses can be with 0.12% alcohol-free chlorhexidine for 5 minutes, half an hour after brushing, povidone-iodine can also be used. [4-6].
- 24) Chlorhexidine gluconate is a broad-spectrum antimicrobial drug with activity against gram-positive and gram-negative organisms, yeasts, and other fungal organisms.
- 25) Chlorhexidine gel can also be applied at home or in concentrations of 1% or 5% in the office, achieving a great reduction in the population of *Streptococcus mutans*. 0.9% saline with or without baking soda can be used if toothpaste causes irritation. Sodium bicarbonate is very useful to neutralize the acidity of the environment generated by hyposialia and thus counteract the appearance of caries.
- 26) Alcohol-containing rinses should be avoided as they can injure the mucosa and aggravate lesions, as well as aggravate xerostomia.
- 27) All these measures must be complemented with the use of dental floss with an atraumatic technique once a day, since chemotherapy will make the soft tissues more labile.
- 28) Swabs can be useful for cleaning the maxillary and mandibular ridges of edentulous areas, the palate, and the tongue. It is important to avoid dry lips to reduce the risk of injury.
- 29) Lip care products contain oils and waxes that can be

helpful.

- 30) Lanolin-based creams and ointments may be more effective in protecting against this type of trauma. This condition can be caused by mouth breathing and xerostomia secondary to anticholinergic medications; among other drugs; used to manage nausea favors it even more. [5-7].

It is also important to use systemic fluoride measures and frequently perform fluoride topicalizations in the office or at home by making individual trays.

The rationale for following the suggested oral hygiene program should be explained to the patient, as well as the possible complications of chemotherapy and radiotherapy for cancer. [6-9].

This oral hygiene routine must be installed a month before cancer therapy so that the patient gets used to it, systematizes it and then its effectiveness must be controlled as well as reinforcing motivation in each consultation. The patient should also be advised, in conjunction with a nutritionist, how to maintain an adequate and complete non-cariogenic diet and recommend the use of complete food supplements before the start of therapy so that in the event of any complication of radiochemotherapy (RQT) the body is in the best conditions to deal with it. [6-9].

The patient should be informed and helped in the total cessation of tobacco and alcohol consumption. The specific protection that the dentist can provide to avoid radiation damage to the bone, teeth, mucosa and salivary glands that are in the vicinity of the tumor is by making acrylic prostheses, in agreement with the radiotherapist, to protect those areas not involved by the tumor. These prostheses are made with 1.25 cm metal plates, thick, composed of 50% bismuth, 26.7% lead, 13.3% zinc and 10% cadmium and coated with acrylic. This will only be used during the RT session.

2.2. Oncospecific Treatment

2.2.1. Surgery

Surgery is the fundamental pillar in buccocervicofacial cancer and within it in the oral cavity. Early diagnosis of these patients is important since the operations are very mutilating and can leave multiple sequelae in addition to exposing the patient to multiple risks and complications. With similar characters, but at the same time dissimilar differences depending on the locations.

In this section we will only emphasize malignant conditions with the primary tumor in the buccomaxillofacial complex. [6-9].

2.2.2. Risks and Surgical Complications According to Locations

(i). Lip Cancer (Figure 1)

Cancer with labial location is characterized by being very evident, so that patients can quickly self-detect any alteration. In the highest percentage of diagnosed cases, squamous cell carcinomas originate in the lining epithelium of the vermillion.

They generally grow slowly and are not as metastatic. In our

experience, the most affected region is the lower lip and it appears infrequently in women. It has great affinity for the white race and manifests itself from the fifth or sixth decade of life. Its diagnosis is easy and relatively early. In its etiopathogenesis it is related to solar radiation mainly in patients with potentially malignant (premalignant) lesions, physical, chemical and/or mechanical trauma. It is a neoplasm with important aesthetic, functional, and psychological conditions. [6-9].

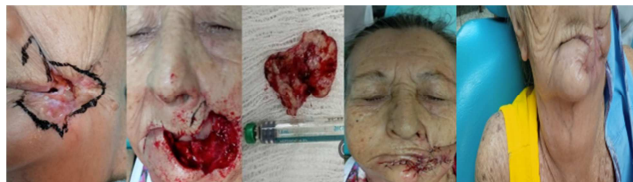

Figure 1. Patient with squamous cell carcinoma of the lower lip and cheek, who was operated on four times, but the wound dehisced, and she came to our clinic for help. Reconstruction was performed with favorable evolution. Courtesy of Doctor Otto Alemán Miranda.

The main objective of surgery is excision with adequate safety margins for the disease and then carry out a reconstruction that results in an aesthetically and functionally acceptable neoplasm for the individual and the professional.

These injuries have a well-studied pattern, of how it evolves. They generally develop in the vermillion mainly in its middle third. It is observed more in the lower lip since this region is exposed more to the sun. [10-12].

Table 1. Main risks and complications of lip cancer.

Cáncer characteristics
Afección estética
Afección funcional
Afección psicológica
Dolor
Infección
Sangrado
Afección ósea
Afección muscular
Metástasis Linfáticas (poco frecuente)
Metástasis a distancia (poco frecuente)
Dificultad para la alimentación
Dificultad para la fonación
Fallecimiento a largo plazo
Del tratamiento quirúrgico
Propios de la anestesia
Lesiones nerviosas
Lesiones vasculares
Dehiscencias de las heridas
Incompetencia labial
Cirugía insuficiente
Recidiva
Persistencia
Cicatrices inestéticas
Microstomía
Babeo
Problemas de dicción
Dificultad para rehabilitarse protésicamente

In its process of local extension, it invades the rest of the vermillion laterally, towards the deep muscles, the skin on the outside and the mucosa of the lip on the inside. Until it

manages to invade the bony portion of the lower or upper jaw. You can use the nerve pathway through the mental and inferior alveolar nerves to the base of the skull. The tumor may continue to other subsites of the oral cavity or outside of it.

(ii). Floor of Mouth

Cancer of the floor of the mouth usually begins in the mucosa of said area, and in its evolution it spreads superficially in a medial direction as if looking for the ventral aspect of the tongue and outwards it is directed against the inner aspect of the mandibular bone, affecting the mucosa of the lingual aspect of the alveolar ridge.

In depth, the condition may include the genioglossus, geniohyoid, and mylohyoid muscles that make up the diaphragm of the buccal floor, in addition to the extrinsic muscles of the tongue. In addition, it can affect all the adjacent structures that are in this area. [10-12].

Table 2. Main risks and complications of cancer of the floor of the mouth.

Propios del Cáncer
Fijación de la lengua
Afección funcional
Afección psicológica
Dolor
Infección
Sangrado
Invasión ósea de la mandíbula (por ruptura de las corticales o vía transalveolar)
Afección muscular
Metástasis Linfáticas
Metástasis a distancia
Dificultad para la alimentación
Dificultad para la fonación
Sialoadenitis Secundaria de la Glándula Submaxilar
Afección de las glándulas sublinguales
Movilidad dental
Toma del nervio dentario inferior
Afección estética por invadir la piel del mentón y del labio inferior produciendo de inicio fijación y edema de la piel y después eritema y ulceración con presencia evidente de la masa tumoral.
Fallecimiento a largo plazo
Del tratamiento quirúrgico
Propios de la anestesia
Lesiones nerviosas
Lesiones vasculares
Dehiscencias de las heridas
Incompetencia labial
Cirugía insuficiente
Recidiva
Persistencia
Cicatrices inestéticas
Disminución de la permeabilidad aérea por edema y/o hematoma postquirúrgico.
Infección
Problemas de dicción
Dificultad para rehabilitarse protésicamente
Riesgos de la traqueostomía
Necrosis de los colgajos a distancia
Dolor severo postquirúrgico
Ingresos prolongados
Tromboembolismos
Necrosis o reabsorción de los injertos óseos
Reacción al material de osteosíntesis
Fallecimiento

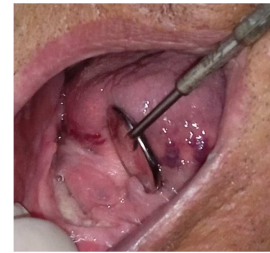

Figure 2. Patient diagnosed with squamous cell carcinoma of the floor of the mouth and inferior residual alveolar ridge. Courtesy of Doctor Otto Alemán Miranda.

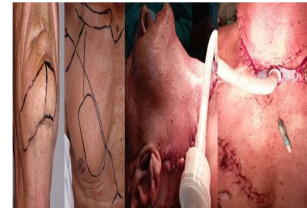

Figure 3. Shows how it was planned and how it turned out at the end of the intervention. Courtesy of Doctor Otto Alemán Miranda.

(iii). Alveolar Ridge (Figure 4)

The carcinoma of the alveolar ridge, in its extension, is closely related to that of the floor of the mouth (see images) and then with the tongue, externally it invades the bottom of the inferior vestibular groove reaching the mucosa of the lip or cheek.

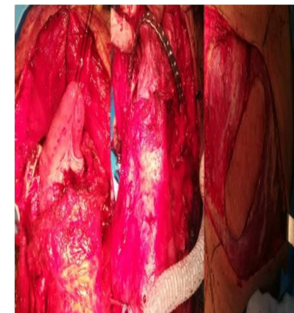


Figure 4. Some steps of the intervention of the previous case are shown. The area after the segmental mandibulectomy, the reconstruction with a metal plate and the conformation of the pectoralis major flap are evident. Courtesy of Doctor Otto Alemán Miranda.

Given its location, its early invasion deep into the underlying bone is frequent. When teeth are present, in most cases severe mobility with subsequent fall of the pieces is common.

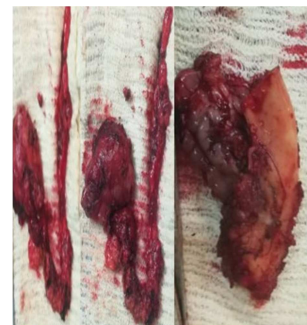

Figure 5. The extracted surgical pieces, lymph node levels and the primary tumor are shown. Courtesy of Doctor Otto Alemán Miranda.

Table 3. Main risks and complications of floor of mouth cancer.

Propios del Cáncer
Fijación de la lengua
Afección funcional
Afección psicológica
Dolor
Infección
Sangrado
Invasión ósea de la mandíbula (por ruptura de las corticales o vía transalveolar)
Afección muscular
Metástasis Linfáticas
Metástasis a distancia
Dificultad para la alimentación
Dificultad para la fonación
Sialoadenitis Secundaria de la Glándula Submaxilar
Afección de las glándulas sublinguales
Movilidad dental
Toma del nervio dentario inferior
Afección estética por invadir la piel del mentón y del labio inferior produciendo de inicio fijación y edema de la piel y después eritema y ulceración con presencia evidente de la masa tumoral.
Parestesias
Neuralgia
Fallecimiento a largo plazo
Del tratamiento quirúrgico
Propios de la anestesia
Lesiones nerviosas
Lesiones vasculares
Dehiscencias de las heridas
Incompetencia labial
Cirugía insuficiente
Recidiva
Persistencia
Cicatrices inestéticas
Disminución de la permeabilidad aérea por edema y/o hematoma postquirúrgico.
Infección
Problemas de dicción
Dificultad para rehabilitarse protésicamente
Riesgos de la traqueostomía
Necrosis de los colgajos a distancia
Dolor severo postquirúrgico
Ingresos prolongados
Tromboembolismos
Necrosis o reabsorción de los injertos óseos
Reacción al material de osteosíntesis
Caída del labio y babeo
Fallecimiento

(iv). Cheek Mucosa (Figure 6)

The neoplastic lesions that begin in the mucosa of the cheek spread locally towards the labial commissure and mucosa of both lips forward. They can affect both the upper and lower buccal vestibules and then invade the bony structures of the mandible or the infrastructure of the maxilla. Backwards they go to the retromolar space, oropharynx and in depth to the masticatory space.

When limited mouth opening is evident, it is a late sign. In their deep infiltration, these tumors take up the thickness of the cheek, invading the buccinator muscle and the subcutaneous cellular tissue of the face, externalizing through the skin of the genian region. Tumors in advanced stages frequently ascend through the soft tissues of the face to enter the infratemporal fossa behind the zygomatic arch. [10-12].

Table 4. Main risks and complications of Carrillo Mucosa cancer.

Propios del Cáncer
Retracción cicatrizal del carrillo
Sialoadenitis por afectación del conducto salival.
Afección psicológica
Deformidad estética de la mejilla.
Dolor
Infección
Sangrado
Invasión ósea de la mandíbula (por ruptura de las corticales o vía transalveolar)
Afección muscular
Metástasis Linfáticas
Metástasis a distancia
Dificultad para la alimentación
Dificultad para la fonación
Limitación de la apertura bucal
Afección estética por invadir la piel de la mejilla y/o los labios, produciendo de inicio fijación y edema de la piel y después eritema y ulceración con presencia evidente de la masa tumoral.
Parestesias
Neuralgia
Fallecimiento a largo plazo
Otras según sitios adyacentes afectados
Del tratamiento quirúrgico
Propios de la anestesia
Lesiones nerviosas
Lesiones vasculares
Dehiscencias de las heridas
Cirugía insuficiente
Recidiva
Persistencia
Cicatrices inestéticas
Infección
Problemas de dicción
Dificultad para rehabilitarse protésicamente
Necrosis de los colgajos a distancia
Dolor severo postquirúrgico
Ingresos prolongados
Tromboembolismos
Fallecimiento

Retraction can be prevented by performing adequate closures without tension, that is, avoiding, as far as possible, secondary intention closure of surgical defects. Surgical defects can be repaired with the use of flap reconstructions. Inflammatory processes of the gland (sialadenitis) can sometimes be avoided by recanalizing the duct, although it usually recedes spontaneously in the immediate postoperative period or after adjuvant radiotherapy. It is important to indicate oral opening and closing exercises in the immediate and mediate postoperative period, in patients where the surgical manipulation affected the muscles of mastication. [10-12].

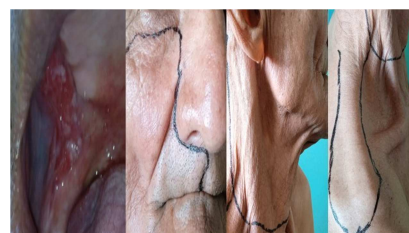

Figure 6. Patient diagnosed with epidermoid carcinoma of the Carrillo mucosa, showing how the intervention was planned. Courtesy of Doctor Otto Alemán Miranda.

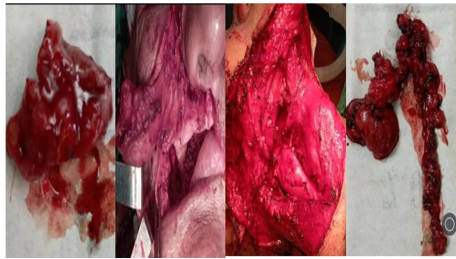


Figure 7. Some steps of the intervention of the previous case and the extracted pieces are shown. Courtesy of Doctor Otto Alemán Miranda.

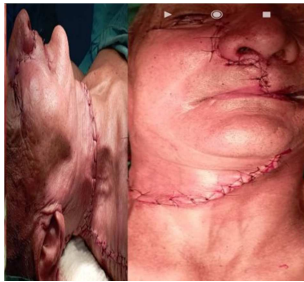

Figure 8. Immediate postoperative period. Courtesy of Doctor Otto Alemán Miranda.

(v). Retromolar Space (Figure 9)

They may extend locally to the cheek mucosa laterally, anterior pillar, soft palate, tonsillar fossa medially, or other portion of the mesopharynx, superior alveolar ridge cephalad, and inferior alveolar ridge caudally.

In depth, these lesions tend to invade the masseter and internal pterygoid muscles, producing limitation of mouth opening. In addition, it can cause seizure of bone tissue at the level of the ramus of the mandible or the tuberosity of the upper maxilla, since both maxillary bones converge in this area. Once in the masticatory space, they extend into the pterygomaxillary and infratemporal fossa. [9-13].

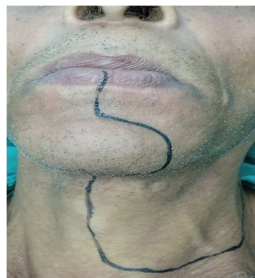

Figure 9. Patient with squamous cell carcinoma of the retromolar space, showing the planning of the surgical approach. Courtesy of Doctor Otto Alemán Miranda.

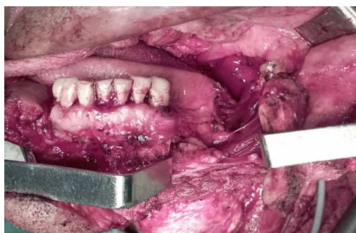

Figure 10. Patient with squamous cell carcinoma of the retromolar space, showing the surgical approach. Courtesy of Doctor Otto Alemán Miranda.

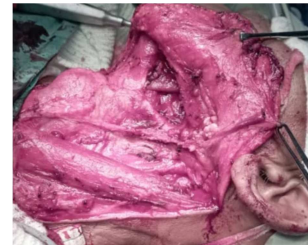

Figure 11. Patient with squamous cell carcinoma of the retromolar space, showing the selective neck dissection already completed. Courtesy of Doctor Otto Alemán Miranda.

Table 5. Main risks and complications of retromolar space cancer.

Propios del Cáncer
Limitación de la apertura bucal
Afección funcional
Afección psicológica
Dolor
Infección
Sangrado
Invasión ósea de la mandíbula (por ruptura de las corticales o vía transalveolar)
Afección muscular
Metástasis Linfáticas
Metástasis a distancia
Dificultad para la alimentación
Dificultad para la fonación
Movilidad dental
Toma del nervio dentario inferior
Parestesias
Neuralgia
Fallecimiento a largo plazo
Del tratamiento quirúrgico
Propios de la anestesia
Lesiones nerviosas
Lesiones vasculares
Dehiscencias de las heridas
Incompetencia labial posterior al abordaje quirúrgico
Cirugía insuficiente
Recidiva
Persistencia
Cicatrices inestéticas
Disminución de la permeabilidad aérea por edema y/o hematoma postquirúrgico.
Infección
Problemas de dicción
Dificultad para rehabilitarse protésicamente
Secuelas estéticas secundarias a la madibulectomía
Necrosis de los colgajos a distancia
Dolor severo postquirúrgico
Ingresos prolongados
Tromboembolismos
Necrosis o reabsorción de los injertos óseos
Reacción al material de osteosíntesis
Fallecimiento

(vi). Tongue (Figure 12)

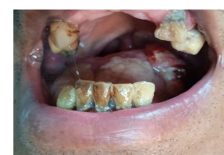

Figure 12. Patient with squamous cell carcinoma of the tongue. Courtesy of Doctor Otto Alemán Miranda.

Squamous cell carcinoma of the tongue frequently occurs on the lateral border and towards the ventral aspect of the tongue. Hence the injury may extend in depth to include the intrinsic muscles and later the extrinsic musculature causing hypomobility or paralysis of the tongue.

Otalgia is a symptom of deep infiltration. Downwards, the tumor invades through the fibers of the hyoglossus muscle, affecting the insertion of the tongue in the hyoid bone and causing its fixation and submental edema. [14].

At the level of the mucosa, the posterior extension produces seizure of the base of the tongue and the rest of the oropharynx, forwards and laterally it invades the floor of the mouth and finally the bony portion of the jaw. In the tongue, the tumor uses the submucosal route for its local extension, hence the importance of palpation in the exam, also once the extrinsic musculature has been taken, the musculoaponeurotic route allows it to go forward to the insertion of the genioglossus and down to the hyoglossus. Embolic dissemination is also a feature of tongue cancer, which is why carcinomatous foci distant from the primary tumor can be found. [15].

Table 6. Main risks and complications of tongue cancer.

Propios del Cáncer
Fijación de la lengua
Afección funcional
Afección psicológica
Dolor
Infección
Sangrado
Invasión ósea de la mandíbula (por ruptura de las corticales o vía transalveolar)
Afección muscular
Metástasis Linfáticas
Metástasis a distancia
Dificultad para la alimentación
Dificultad para la fonación
Sialoadenitis Secundaria de la Glándula Submaxilar
Afección de las glándulas sublinguales
Parestesias
Neuralgia
Caquexia por la imposibilidad para la alimentación
Hemorragia masiva por estallamiento de la carótida o alguna de sus ramas
Fallecimiento a largo plazo
Del tratamiento quirúrgico
Propios de la anestesia
Lesiones nerviosas
Lesiones vasculares
Dehiscencias de las heridas
Incompetencia lingual
Cirugía insuficiente
Recidiva
Persistencia
Cicatrices inestéticas
Disminución de la permeabilidad aérea por edema y/o hematoma postquirúrgico.
Infección
Problemas de dicción
Riesgos de la traqueostomía
Necrosis de los colgajos a distancia
Dolor severo postquirúrgico
Ingresos prolongados
Tromboembolismos
Reacción al material de osteosíntesis en el sitio de abordaje
Fallecimiento

(vii). Paladar Duro

They immediately infiltrate the bone tissue, extending to the nostrils and to the maxillary sinus, posteriorly it affects the soft palate, towards the anterolateral portion it takes the alveolar ridges and upper buccal vestibules, producing dental mobility and loss of dental organs.

It should be ruled out as long as it is not a lesion of the nasal fossa or maxillary sinus that has descended through the infrastructure. Regional spread is rare and occurs to the nodes of the upper third of the group II jugular, especially when the lesion has spread to the soft palate. [16-17].

Table 7. Main risks and complications of hard palate cancer.

Propios del Cáncer
Comunicación Oronasal u oro-antral
Afección funcional
Afección psicológica
Dolor
Infección
Sangrado
Invasión ósea del maxilar (por ruptura de las corticales o vía transalveolar)
Afección muscular
Metástasis Linfáticas
Metástasis a distancia
Dificultad para la alimentación
Dificultad para la fonación
Movilidad dental
Toma del nervio dentario superior
Parestesias
Neuralgia
Rinolalia y regurgitación nasal de los alimentos
Fallecimiento a largo plazo
Del tratamiento quirúrgico
Propios de la anestesia
Lesiones nerviosas
Lesiones vasculares
Dehiscencias de las heridas
Cirugía insuficiente
Recidiva
Persistencia
Cicatrices inestéticas
Infección
Problemas de dicción
Dificultad para rehabilitarse protésicamente
Necrosis de los colgajos a distancia
Dolor severo postquirúrgico
Ingresos prolongados
Tromboembolismos
Necrosis o reabsorción de los injertos óseos
Reacción al material de osteosíntesis
Fallecimiento

3. Conclusion

The main complications and risks of oral cancer were described by anatomical regions, as well as the sequelae of surgical procedures. Supported by an exhaustive review of the literature, as well as the previous experience of the author. This disease has a high mortality rate at the international level, and causes multiple physical, mental and social conditions.

Acknowledgements

To my wife for all her unconditional professional and personal support.

References

- [1] Atlas de Patología del Complejo Bucal. (Atlas of Pathology of the Buccal Complex.) Julio C. Santana Garay. 2 ed. Editorial de Ciencias Médicas. La Habana. 2010. Cap. 12. PÁG. 315.
- [2] ATSDR en Español. ¿Qué es el cáncer? ATSDR in Spanish. What is cancer?. 2010 (On-line); [2 páginas] Disponible en: <http://www.atsdr.cdc.gov/es/general/cancer/> Consultado Abril 12, 2022, pág. 2.
- [3] Barclay SC, Turani D. Current practice in dental oncology in the U.K. Dent. Update. 2010; 37 (8): 555-561.
- [4] Nakashima T, Tomita H, Hirata A, Ishida K, Hisamatsu K, Hatano Y, et al. Promotion of cell proliferation by the proto-oncogene DEK enhances oral squamous cell carcinogenesis through field cancerization. Cancer Med. 2017; 6: 2424–39. [PMC free article] [PubMed] [Google Scholar] [citado en mayo del 2022].
- [5] Cirugía de Cabeza y cuello. Head and neck surgery. Dr. Robert A. Wise, Dr. Harvey W. Baker. 3ed. [Nueva Editorial Interamericana? [s.a] Cap 2. PÁG. 24. [citado en mayo del 2022].
- [6] De Vita Jr VT, Hellman S, Rosenberg SA. Cancer. Principles & practice of oncology. 5ed. Philadelphia: Lippincott-Raven, 1997.
- [7] Disección ganglionar de cuello: conceptos actuales. Neck lymph node dissection: current concepts. Enrique Cadena, Álvaro Sanabria. Revista colombiana cancerol. 2011; 15 (3): 145-154. [citado en mayo del 2022].
- [8] Dr. Emilio Rodríguez Ricardo, Dr. Kadir Argelio Santana Fernández. Evaluación del programa de detección precoz del cáncer bucal, Evaluation of the oral cancer early detection program. Revista Archivo Médico de Camagüey versión ISSN 1025-0255. 2014. [citado en mayo del 2022].
- [9] Ecurrred, Generalidades del Cáncer bucal. Colectivo de autores. Oral Cancer Overview. Collective of authors. 2013. Pág. 1. [citado en mayo del 2022].
- [10] Ferlito A, Robbins KT, Silver CE, et al. Classification or neck dissections: an evolving system. Auris Nasus Larynx. 2009; 36: 127-34. [citado en mayo del 2022].
- [11] Ferlito A, Robbins T, Shah JP, et al. Proposal for a rational classification of neck dissections. Head Neck. 2011; 33: 445-50. [citado en mayo del 2022].
- [12] Woo BH, Kim DJ, Choi JI, Kim SJ, Park BS, Song JM, et al. Oral cancer cells sustainedly infected with Porphyromonas gingivalis exhibit resistance to Taxol and have higher metastatic potential. Oncotarget. 2017; 8: 46981–92. [PMC free article] [PubMed] [Google Scholar].
- [13] Hayes RB, Ahn J, Fan X, Peters BA, Ma Y, Yang L, et al. Association of oral microbiome with risk for incident head and neck squamous cell cancer. JAMA Oncol. 2018; 4: 358–65. [PMC free article] [PubMed] [Google Scholar].
- [14] González-Moles MA, García-Asensio J. Efectos adversos del tratamiento del cáncer oral. Adverse effects of oral cancer treatment. En: González-Moles MA (ed). Precáncer y cáncer oral. Madrid: Ed Avances Medico-Dentales S. L. 2001. p. 189-218.
- [15] Sathiasekar AC, Mathew DG, Jaish Lal MS, Arul Prakash AA, Goma Kumar KU. Oral field cancerization and its clinical implications in the management in potentially malignant disorders. J Pharm Bioallied Sci. 2017; 9 (Suppl 1): S23–5. [PMC free article] [PubMed] [Google Scholar].
- [16] Lanza Echeveste, D. G.: Tratamiento odontológico integral del paciente oncológico. Comprehensive dental treatment of cancer patients. Parte 1. Odontostomatología. Mayo 2011; XIII, (17): 14-25.
- [17] Khan Z, Dreger S, Shah SMH, Pohlabein H, Khan S, Ullah Z, et al. Oral cancer via the bargain bin: The risk of oral cancer associated with a smokeless tobacco product (Naswar) PloS one. 2017; 12: e0180445. [PMC free article] [PubMed] [Google Scholar].